



eBook for Undergraduate Education in Radiology

| CHAPTER: Breast Imaging



Preface

Undergraduate teaching of radiology in Europe is provided according to national schemes and may vary considerably from one academic institution to another. Sometimes, the field of radiology is considered as a “cross-cutting discipline” or taught within the context of other clinical disciplines, e.g., internal medicine or surgery.

This e-book has been created in order to serve medical students and academic teachers throughout Europe to understand and teach radiology as a whole coherent discipline, respectively. Its contents are based on the *Undergraduate Level of the ESR European Training Curriculum for Radiology* and summarize the so-called **core elements** that may be considered as the basics that every medical student should be familiar with. Although specific radiologic diagnostic skills for image interpretation cannot be acquired by all students and rather belong to the learning objectives of the *Postgraduate Levels of the ESR Training Curricula*, the present e-book also contains some **further insights** related to modern imaging in the form of examples of key pathologies, as seen by the different imaging modalities. These are intended to give the interested undergraduate student an understanding of modern radiology, reflecting its multidisciplinary character as an organ-based specialty.

We would like to extend our special thanks to the authors and members of the ESR Education Committee who have contributed to this eBook, to Carlo Catalano, Andrea Laghi and András Palkó who initiated this project, and to the ESR Office, in particular Bettina Leimberger and Danijel Lepir, for all their support in realising this project.

We hope that this ebook may fulfil its purpose as a useful tool for undergraduate academic radiology teaching.

Minerva Becker
ESR Education Committee Chair

Vicky Goh
ESR Undergraduate Education Subcommittee Chair

Chapter Outline

Breast Anatomy

Anatomical Variants

Pregnancy and Lactation

Diagnostic Imaging Techniques

Disease of the Breast: Benign

Disease of the Breast: Malignant

Axilla

Interventional Procedures

Screening

High Risk Women

Communication

Multidisciplinary Team Meeting

Take-Home Messages

References

Test Your Knowledge



Copyright and Terms of Use

This work is licensed under a [Creative Commons Attribution-NonCommercial-NoDerivatives 4.0 International License](https://creativecommons.org/licenses/by-nc-nd/4.0/).

You are free to:

- **Share** – copy and redistribute the material in any medium or format

Under the following terms:

- **Attribution** – You must give appropriate credit, provide a link to the license, and indicate if changes were made. You may do so in any reasonable manner, but not in any way that suggests the licensor endorses you or your use.
- **NonCommercial** – You may not use the material for commercial purposes.
- **NoDerivatives** – If you remix, transform, or build upon the material, you may not distribute the modified material.

How to cite this work:

European Society of Radiology, Federica Pediconi, Fiona J. Gilbert, Francesca Galati, Filipe Barros Alves, Pascal A.T. Baltzer, Melis Baykara Ulasan, Paola Clauser, Francesca Ferrara, Elisabetta Giannotti, Fleur Kilburn-Toppin, Maria Adele Marino, Jessica Muscat, Simone Schiaffino, Rubina Manuela Trimboli, Chantal Van Ongeval, Thiemo J.A. van Nijnatten, Giulia Vatteroni, Mirjam Wielema (2023) eBook for Undergraduate Education in Radiology: Breast Imaging. DOI 10.26044/esr-undergraduate-ebook-14

Chapter Outline

Breast Anatomy

Anatomical Variants

Pregnancy and Lactation

Diagnostic Imaging Techniques

Disease of the Breast: Benign

Disease of the Breast: Malignant

Axilla

Interventional Procedures

Screening

High Risk Women

Communication

Multidisciplinary Team Meeting

Take-Home Messages

References

Test Your Knowledge



Hyperlinks



Core Knowledge



Further Knowledge



Attention



Compare



Questions



References

Chapter Outline

Breast Anatomy

Anatomical Variants

Pregnancy and Lactation

Diagnostic Imaging Techniques

Disease of the Breast: Benign

Disease of the Breast: Malignant

Axilla

Interventional Procedures

Screening

High Risk Women

Communication

Multidisciplinary Team Meeting

Take-Home Messages

References

Test Your Knowledge



eBook for Undergraduate Education in Radiology

Based on the ESR Curriculum for Undergraduate Radiological Education

Chapter: Breast Imaging

Authors

Editors:	Authors:	Filipe Barros Alves	Elisabetta Giannotti	Simone Schiaffino
Federica Pediconi		Pascal A.T. Baltzer	Fiona J. Gilbert	Rubina Manuela Trimboli
Fiona J. Gilbert		Melis Baykara Ulasan	Fleur Kilburn-Toppin	Chantal Van Ongeval
		Paola Clauser	Maria Adele Marino	Thiemo J.A. van Nijnatten
Assistant Editor:		Francesca Ferrara	Jessica Muscat	Giulia Vatteroni
Francesca Galati		Francesca Galati	Federica Pediconi	Mirjam Wielema

Affiliation

European Society of Breast Imaging (EUSOBI)

Chapter Outline

- Breast Anatomy
- Anatomical Variants
- Pregnancy and Lactation
- Diagnostic Imaging Techniques
- Disease of the Breast: Benign
- Disease of the Breast: Malignant
- Axilla
- Interventional Procedures
- Screening
- High Risk Women
- Communication
- Multidisciplinary Team Meeting
- Take-Home Messages
- References
- Test Your Knowledge





Chapter Outline (1)

- **Breast Anatomy**

- Introduction
- Nipple-areola complex
- Breast density
- Quadrant anatomy
- Structure: lobes and lobules
- Breast anatomy during pregnancy and lactation
- Male breast: Anatomy and gynaecomastia

- **Anatomical Variants**

- Normal Variations in Development
- Gynecomastia
- Congenital and development abnormalities
- Acquired development abnormalities

- **Pregnancy and Lactation**

- Pregnancy
- Partum
- Lactation

- **Diagnostic Imaging Techniques**

- Mammography
- DBT
- US
- MRI
- CEM

- **Diseases of the Breast: Benign**

- Cysts
- Fibrocystic change
- Fibroadenoma
- Phylloides tumour
- Hamartoma
- Lipoma and Angiolipoma
- Mastitis/Abscess
- Hematoma
- Fat Necrosis

Chapter Outline

Breast Anatomy

Anatomical Variants

Pregnancy and Lactation

Diagnostic Imaging Techniques

Disease of the Breast: Benign

Disease of the Breast: Malignant

Axilla

Interventional Procedures

Screening

High Risk Women

Communication

Multidisciplinary Team Meeting

Take-Home Messages

References

Test Your Knowledge



Chapter Outline (2)

- **Disease of the Breast: Malignant**
- **Axilla**
 - Anatomy
 - Appearance on ultrasound
 - Intervention
- **Interventional Procedures**
 - Fine-needle aspiration cytology (FNAC)
 - Core needle biopsy (CNB)
 - Vacuum assisted biopsy (VAB)
 - Vacuum assisted excision (VAE)
 - Pre-operative localization
 - Minimal invasive therapy
- **Screening**
 - What is screening?
 - Aim of breast screening
 - Risk factors
 - How to screen
 - Limitations of screening
- **High Risk Women**
 - Introduction
 - Average risk
 - Intermediate risk
 - History
 - Density
 - High risk

Chapter Outline

Breast Anatomy

Anatomical Variants

Pregnancy and Lactation

Diagnostic Imaging Techniques

Disease of the Breast: Benign

Disease of the Breast: Malignant

Axilla

Interventional Procedures

Screening

High Risk Women

Communication

Multidisciplinary Team Meeting

Take-Home Messages

References

Test Your Knowledge



Chapter Outline (3)

- **Communication**

- Mammography – indications and Recommendations
- Ultrasound – Indications
- Triple assessment
- Breast imaging scenarios
- Basic considerations in communicating with patients

- **Multidisciplinary Team Meeting**

- Considerations in communicating with health professionals
- Multidisciplinary Team Meeting

- **Take-Home Messages**

- **References**

- **Test Your Knowledge**

Chapter Outline

Breast Anatomy

Anatomical Variants

Pregnancy and Lactation

Diagnostic Imaging Techniques

Disease of the Breast: Benign

Disease of the Breast: Malignant

Axilla

Interventional Procedures

Screening

High Risk Women

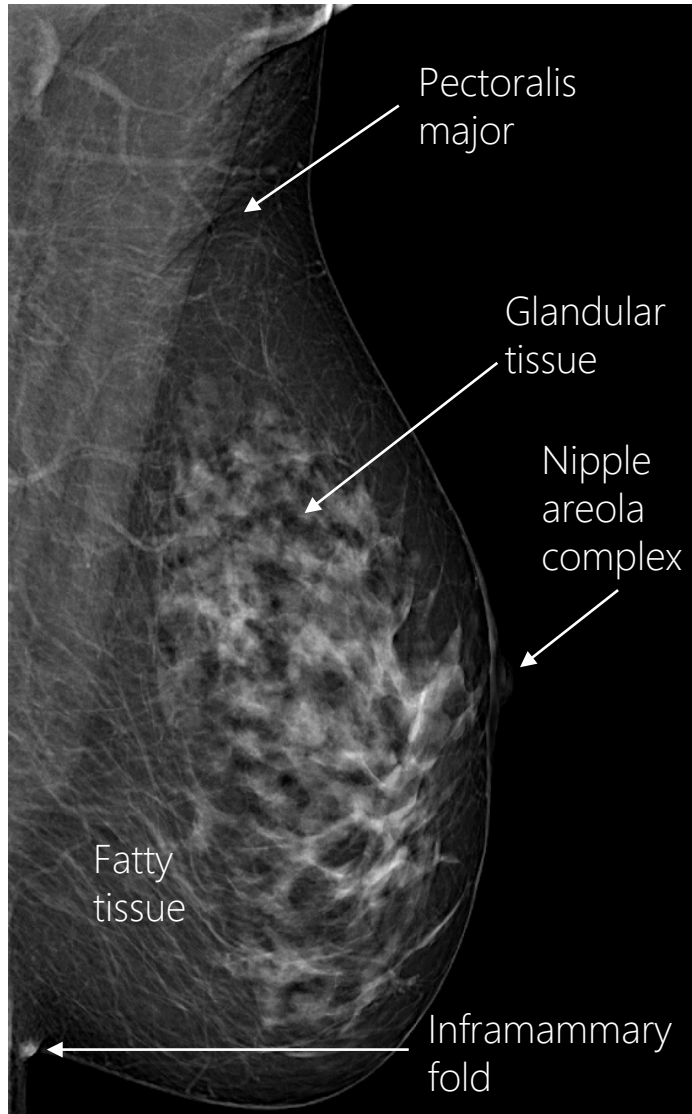
Communication

Multidisciplinary Team Meeting

Take-Home Messages

References

Test Your Knowledge



Introduction




- Female breasts are skin annexes, equal and symmetrical, with breastfeeding as their main function.
- The breast is covered with skin, and at the apex it has a rounded pigmented area, the areola, in the center of which the nipple protrudes, resulting in the nipple areola complex (NAC).
- Until puberty, the appearance and volume of the breasts are similar in both sexes. In women, when the breast develops, there can be notable variation in volume. Breast volume and texture are under the influence of genetic and endocrine stimuli. After puberty, in the male, the glandular part does not develop and, therefore, the breasts remain structurally in the prepubertal state for lifetime. In the female, at puberty, the breasts develop, with growth occurring by proliferation of all the components of the organ (parenchymal tissue, periductal stroma and interstitial connective tissue).

Chapter Outline

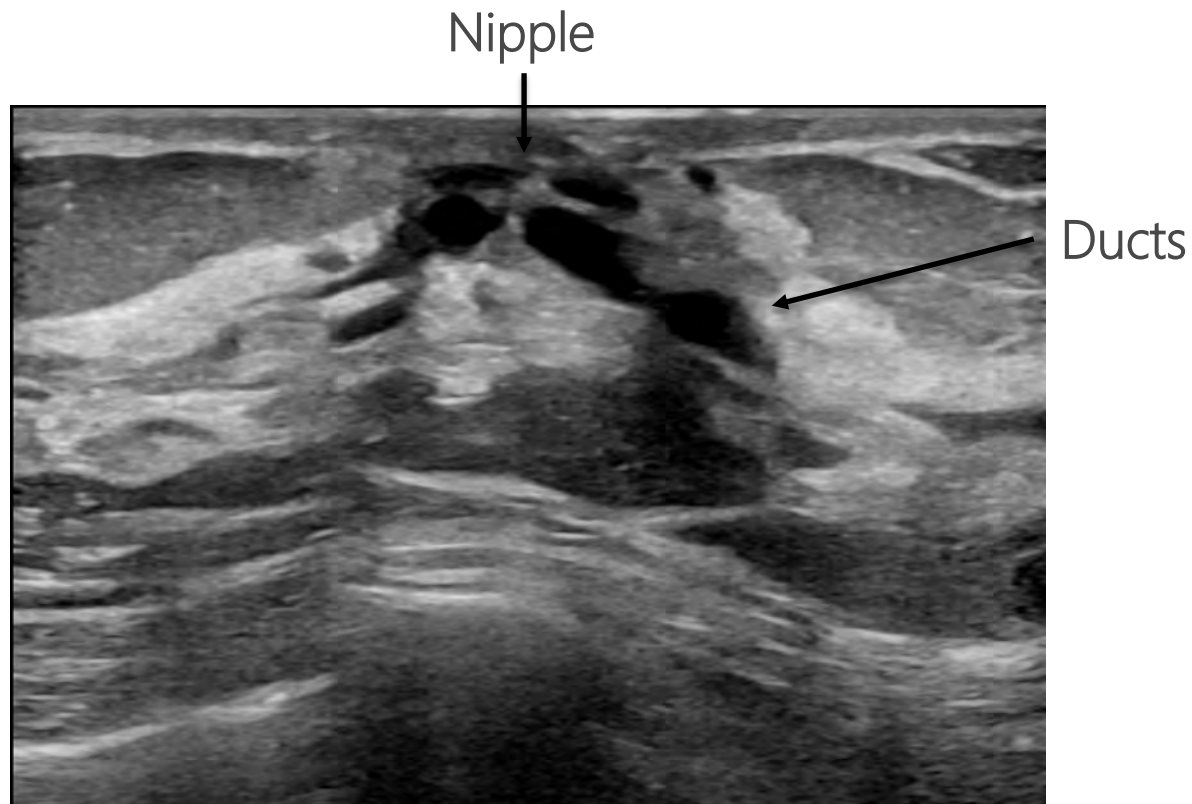
- ▶ **Breast Anatomy**
 - ▶ Introduction
- Anatomical Variants**
- Pregnancy and Lactation**
- Diagnostic Imaging Techniques**
- Disease of the Breast: Benign**
- Disease of the Breast: Malignant**
- Axilla**
- Interventional Procedures**
- Screening**
- High Risk Women**
- Communication**
- Multidisciplinary Team Meeting**
- Take-Home Messages**
- References**
- Test Your Knowledge**



Nipple-Areola Complex



Ultrasound (US) anatomy of the confluence of the ducts in the nipple areola complex in a normal breast. The ducts are identifiable as anechoic tubular structures that are oriented towards the nipple.

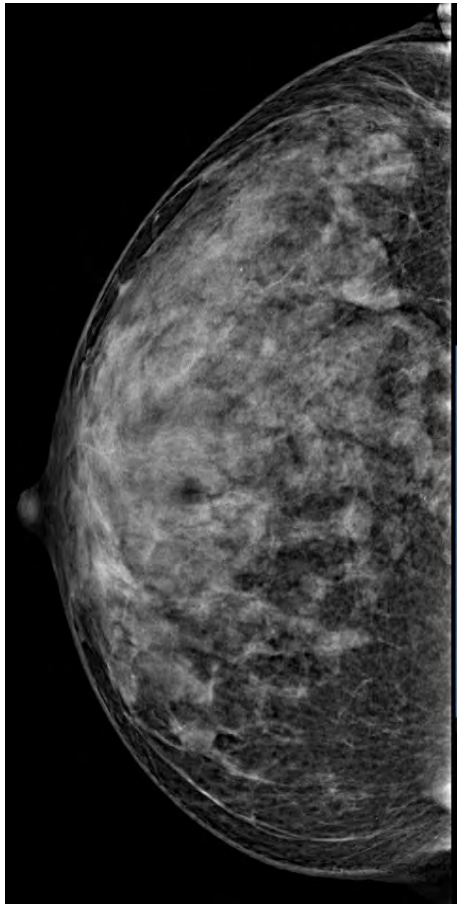



Chapter Outline

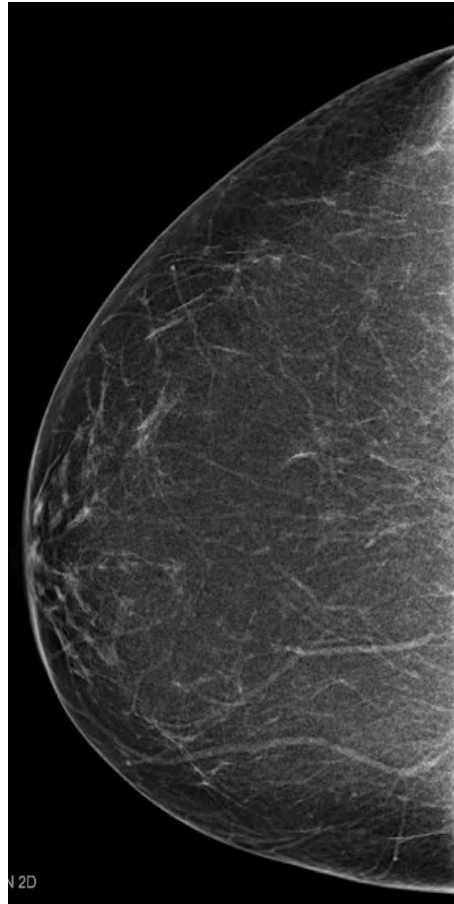
- ▶ **Breast Anatomy**
 - ▶ Nipple-Areola Complex
- Anatomical Variants**
- Pregnancy and Lactation**
- Diagnostic Imaging Techniques**
- Disease of the Breast: Benign**
- Disease of the Breast: Malignant**
- Axilla**
- Interventional Procedures**
- Screening**
- High Risk Women**
- Communication**
- Multidisciplinary Team Meeting**
- Take-Home Messages**
- References**
- Test Your Knowledge**



Breast Density



Extremely dense



Almost entirely fatty

Breast density is due to fibroglandular tissue. This varies during the menstrual cycle due to proliferation of the epithelial cells and increased vascularity.

There is an increase in volume in pregnancy due to the development of the alveoli and related ducts.

At menopause, the glandular component of the breasts undergoes atrophy, while the connective support structures tend to relax. Hormone replacement therapy can increase breast density or prevent involution of breast glandular tissue.



The quantity of glandular and connective components is classified on mammography by the **ACR BI-RADS¹** into 4 categories:

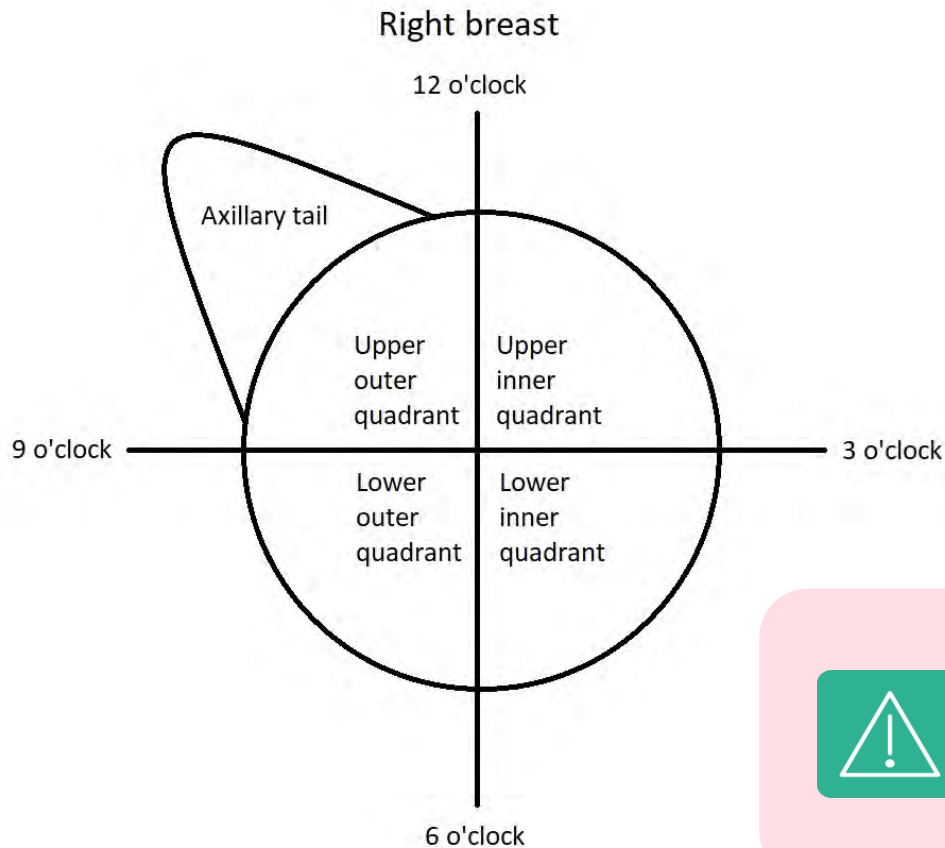
- a: almost entirely fatty,
- b: scattered areas of fibroglandular density,
- c: heterogeneously dense, and
- d: extremely dense.

Chapter Outline

- ▶ **Breast Anatomy**
 - ▶ Breast Density
- Anatomical Variants**
- Pregnancy and Lactation**
- Diagnostic Imaging Techniques**
- Disease of the Breast: Benign**
- Disease of the Breast: Malignant**
- Axilla**
- Interventional Procedures**
- Screening**
- High Risk Women**
- Communication**
- Multidisciplinary Team Meeting**
- Take-Home Messages**
- References**
- Test Your Knowledge**



Quadrant Anatomy



Two perpendicular axes passing through the nipple divide the breast into four quadrants.

The axillary tail is added adjacent to the upper-external quadrant. Furthermore, the hours of the clock can be used to locate any focal lesion, adding the distance to the nipple, as shown in the figure.



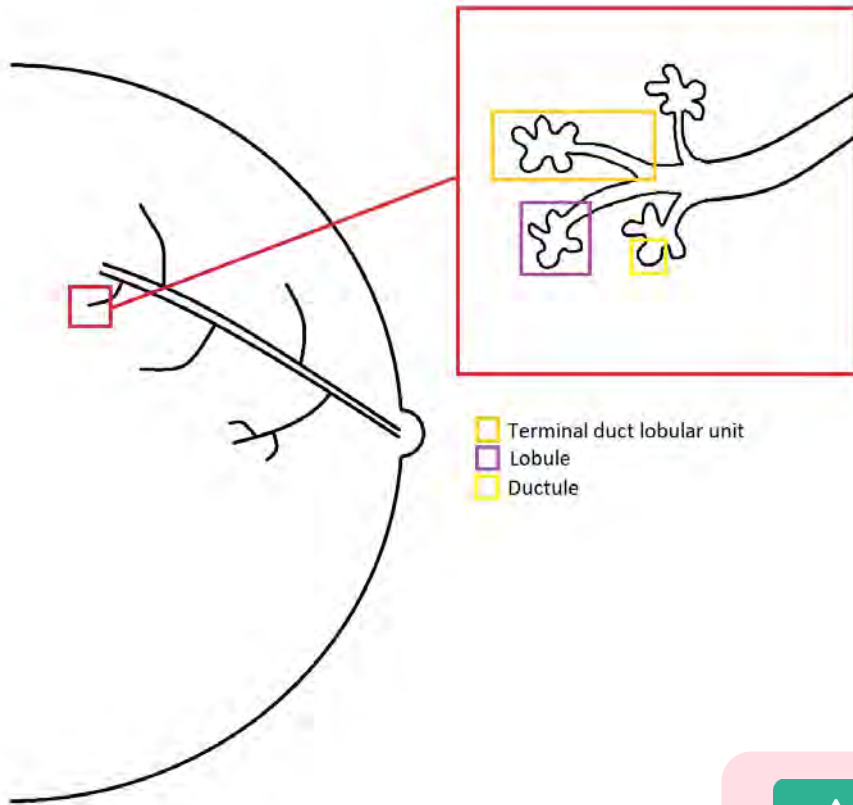
The upper-outer quadrant is the one with the largest amount of glandular tissue and, therefore, is more frequent site of breast cancer.

Chapter Outline

- ▶ **Breast Anatomy**
 - ▶ Quadrant Anatomy
- Anatomical Variants**
- Pregnancy and Lactation**
- Diagnostic Imaging Techniques**
- Disease of the Breast: Benign**
- Disease of the Breast: Malignant**
- Axilla**
- Interventional Procedures**
- Screening**
- High Risk Women**
- Communication**
- Multidisciplinary Team Meeting**
- Take-Home Messages**
- References**
- Test Your Knowledge**



Structure: Lobes and Lobules



The breast contains glandular, fatty and connective tissue.

The glandular tissue (a modified apocrine gland) is divided in lobules, and produces the milk, which is drained by the mammary ducts to the nipple. The nipple areola complex (NAC) is part of the visible breast.

Connective bundles (retinacles) divide the glandular tissue into lobes and lobules.

Each breast has 12-20 lobes drained by a separate main duct per lobe.

Each lobe includes several lobules of glandular tissue, also referred as terminal ductal lobular units (TDLU) and mammary ducts carrying milk from lobules to the nipple.



TDLUs are epithelial structures that produces milk during lactation and are the main source of breast neoplasms precursors and cancers.

Chapter Outline

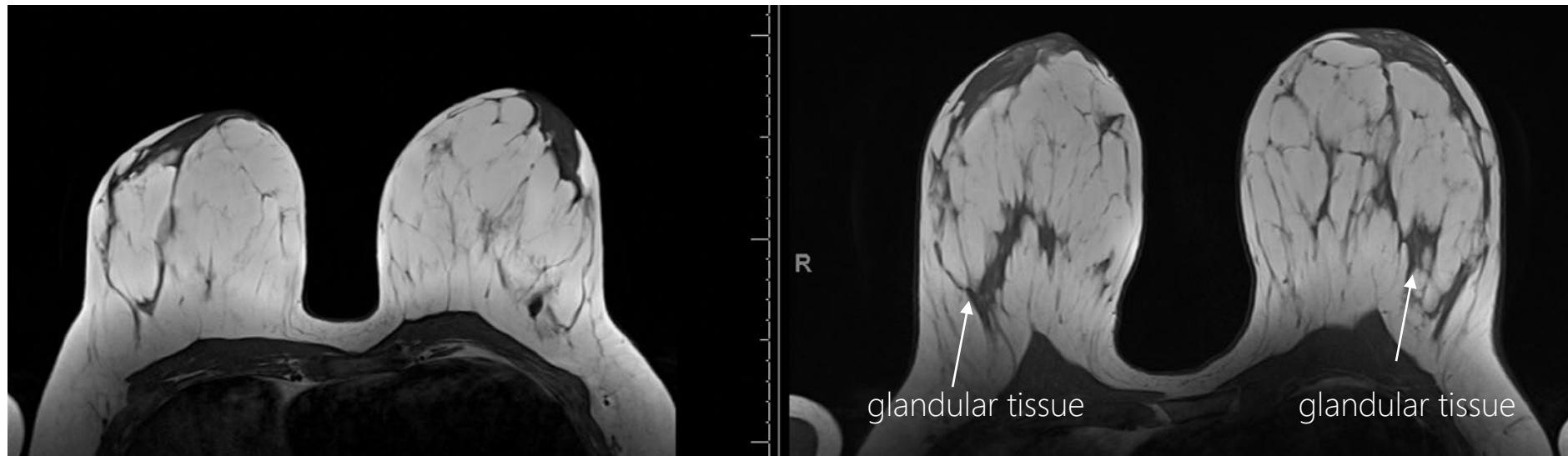
- ▶ **Breast Anatomy**
 - ▶ Structure: Lobes and Lobules
- Anatomical Variants**
- Pregnancy and Lactation**
- Diagnostic Imaging Techniques**
- Disease of the Breast: Benign**
- Disease of the Breast: Malignant**
- Axilla**
- Interventional Procedures**
- Screening**
- High Risk Women**
- Communication Multidisciplinary**
- Team Meeting Take-Home**
- Messages References**
- Test Your Knowledge**



Breast Anatomy During Pregnancy and Lactation



During the second month of gestation the breasts grow due to lobular enlargement of the TDLUs and new TDLUs are formed. During the 3rd and 4th month of gestation the lobular glands distend even more due to accumulation of secretions. Early lactation is accompanied by a further increase in the volume of the breasts, especially in the glandular component.



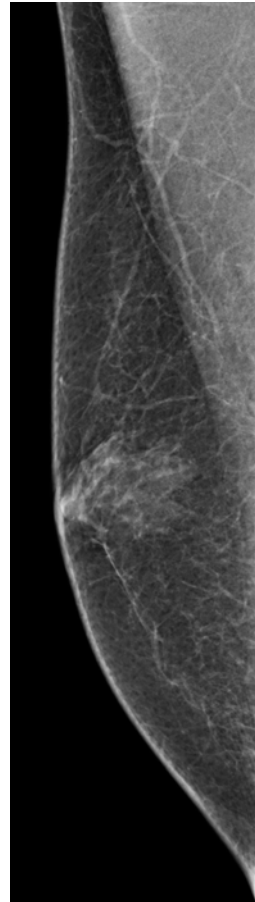
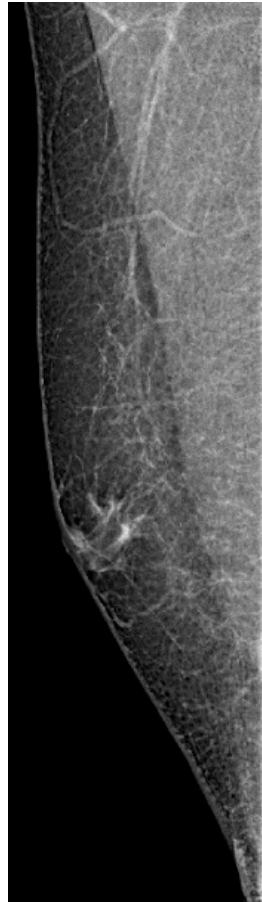T1-weighted sequences before and during pregnancy in the same patient. There is an evident increase in volume and in the glandular tissue bilaterally.

Chapter Outline

- ▶ **Breast Anatomy**
 - ▶ Breast Anatomy During Pregnancy and Lactation
- Anatomical Variants**
- Pregnancy and Lactation**
- Diagnostic Imaging Techniques**
- Disease of the Breast: Benign**
- Disease of the Breast: Malignant**
- Axilla**
- Interventional Procedures**
- Screening**
- High Risk Women**
- Communication**
- Multidisciplinary Team Meeting**
- Take-Home Messages**
- References**
- Test Your Knowledge**



Male Breast: Anatomy and Gynaecomastia



Normal male breast

Gynecomastia

In the male, the breast appear as a small, even and symmetrically located on the mid-clavicular line, at the level of the 4th intercostal space.

Structurally, the male breast is comparable to the female one before puberty. The glandular body is atrophic, in which the connective stromal tissue is dominant over the epithelial parenchyma.

At puberty, the male breast can undergo a temporary hypertrophy (**gynecomastia**), mostly unilateral, due to transient hormonal imbalance, with a prevalence of estrogen over androgens.

At older age gynecomastia can develop due to the use of several drugs.

Chapter Outline

- ▶ **Breast Anatomy**
 - ▶ Male Breast: Anatomy and Gynaecomastia
- Anatomical Variants**
- Pregnancy and Lactation**
- Diagnostic Imaging Techniques**
- Disease of the Breast: Benign**
- Disease of the Breast: Malignant**
- Axilla**
- Interventional Procedures**
- Screening**
- High Risk Women**
- Communication**
- Multidisciplinary Team Meeting**
- Take-Home Messages**
- References**
- Test Your Knowledge**

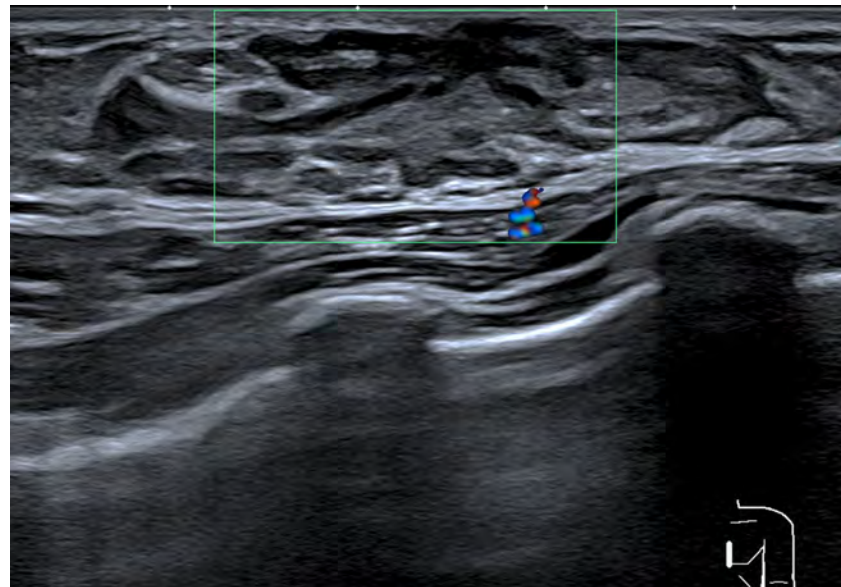
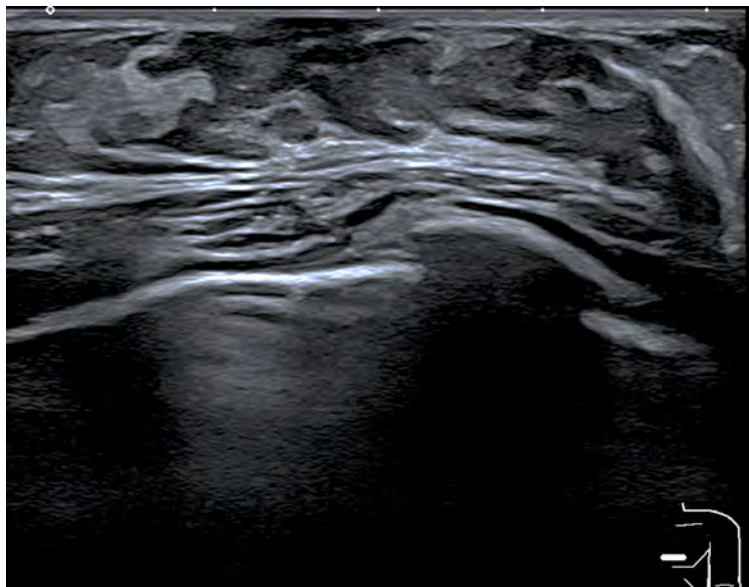


Normal Variations in Development



PREMATURE THELARCHE: breast development <7½ years, unilateral/bilateral, normal breast tissue on US

Idiopathic premature thelarche: 1-3 years old unusual after 4 years, self-limited



Ultrasound of 3 years old girl in presence of palpable lump behind left nipple shows breast bud/ normal breast tissue in keeping with premature thelarche

Chapter Outline

Breast Anatomy

- ▶ Anatomical Variants
 - ▶ Normal Variations in Development

Pregnancy and Lactation

Diagnostic Imaging Techniques

Disease of the Breast: Benign

Disease of the Breast: Malignant

Axilla

Interventional Procedures

Screening

High Risk Women

Communication

Multidisciplinary Team Meeting

Take-Home Messages

References

Test Your Knowledge



Gynecomastia



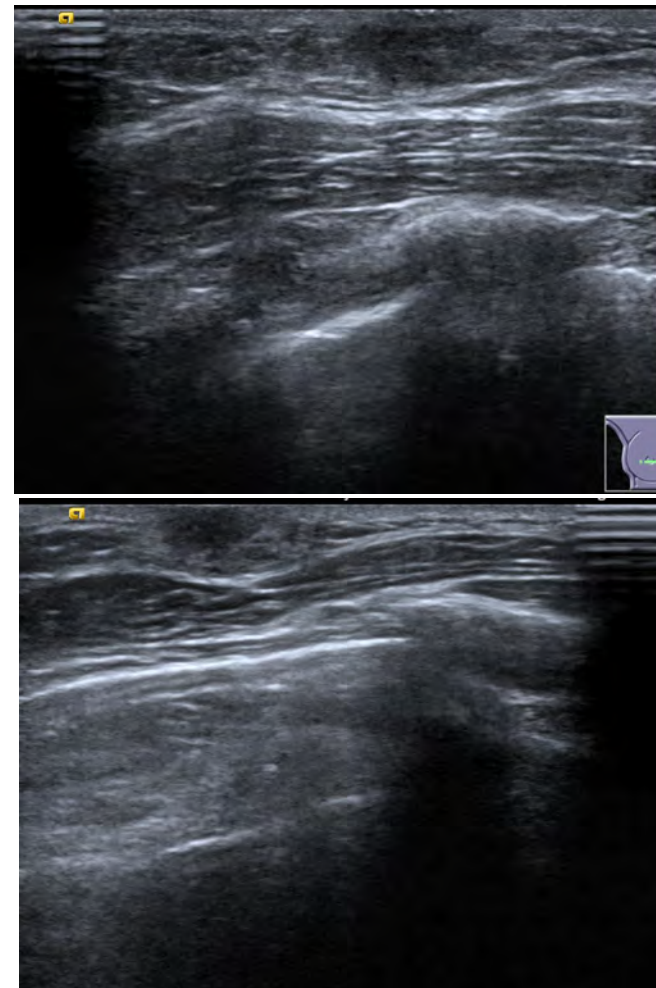
=> excessive development of the breast tissue in male:

Physiologic:

- In 90% of neonates transient breast hypertrophy due to maternal hormone
- 1 year after puberty and for 1-2 years (75% healthy boys)

Further causes:

- Anabolic steroids, digitalis, isoniazid, tricyclic antidepressants, marijuana
- General obesity: pseudo gynecomastia
- Klinefelter syndrome, anorchism, acquired testicular failure androgen receptor defects



Ultrasound shows typical US appearance of gynecomastia

Chapter Outline

Breast Anatomy

- ▶ **Anatomical Variants**
 - ▶ Gynecomastia

Pregnancy and Lactation

Diagnostic Imaging Techniques

Disease of the Breast: Benign

Disease of the Breast: Malignant

Axilla

Interventional Procedures

Screening

High Risk Women

Communication

Multidisciplinary Team Meeting

Take-Home Messages

References

Test Your Knowledge



Congenital and Developmental Abnormalities



= anomalous nipple and breast development

- **Polythelia** => accessory nipples, most common
- **Polymastia** => accessory tissue incomplete involution of mammary ridge, usually enlarged during pregnancy and lactation
- **Amastia** => absence of breast development
- **Hyperplasia** and **Hypoplasia** => unilateral or bilateral
- **Congenital inversion of nipple** (3%) associated with duct ectasia, periductal mastitis
- **Ectopic breast tissue**: along the mammary ridge or milk line. Incomplete involution of ectodermal mammary ridge. Most common in the axilla (2-6% women).
- **Poland syndrome** => child born with missing or underdeveloped pectoralis muscle, breast hypoplasia or aplasia, rib and chest wall deformities, and ipsilateral limb abnormalities [rare 1/36.000-50.000]

Chapter Outline

Breast Anatomy

- ▶ **Anatomical Variants**
 - ▶ Congenital and Developmental Abnormalities

Pregnancy and Lactation

Diagnostic Imaging Techniques

Disease of the Breast: Benign

Disease of the Breast: Malignant

Axilla

Interventional Procedures

Screening

High Risk Women

Communication

Multidisciplinary Team Meeting

Take-Home Messages

References

Test Your Knowledge



Congenital and Developmental Abnormalities



Chapter Outline

Breast Anatomy

- ▶ **Anatomical Variants**
 - ▶ Congenital and Developmental Abnormalities

Pregnancy and Lactation

Diagnostic Imaging Techniques

Disease of the Breast: Benign

Disease of the Breast: Malignant

Axilla

Interventional Procedures

Screening

High Risk Women

Communication

Multidisciplinary Team Meeting

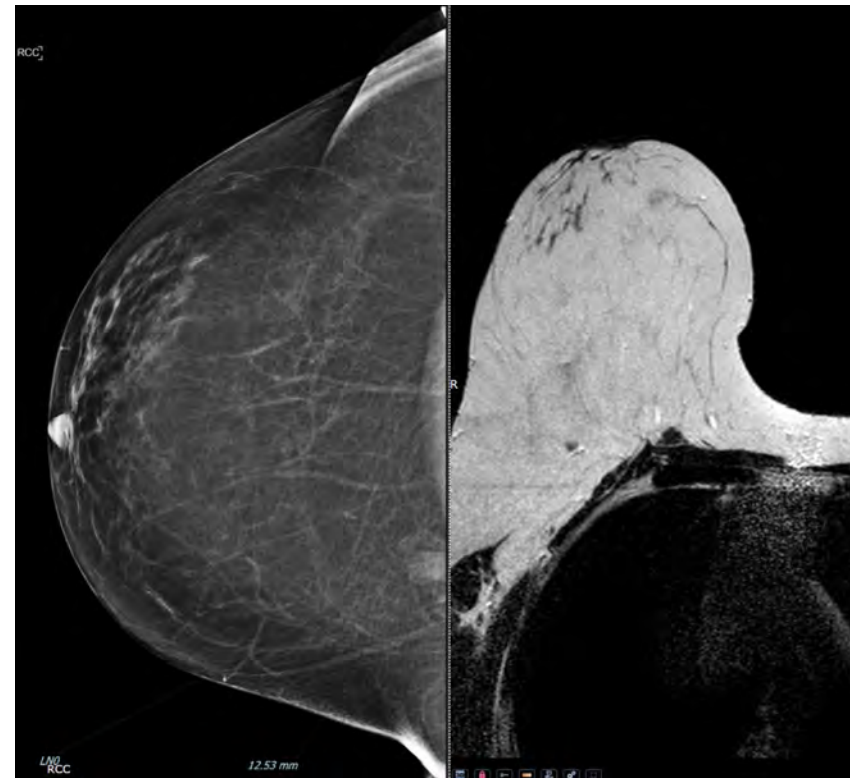
Take-Home Messages

References

Test Your Knowledge

Sternalis muscle:

- Uncommon anatomic variant of the chest wall musculature.
- Often cause of false positives in mammography



Mammogram and MRI images of sternalis muscle



Pregnancy



Physiological changes in the architecture of the breast to prepare for breast feeding (increased serum level of oestrogen, progesterone and prolactin)

- **Marked ductal and lobular proliferation in early weeks of pregnancy**
- **Weeks 5-9** generalised breast enlargement and progressive increase in nipple-areolar complex pigmentation
- **First trimester** Under the influence of oestrogen, ductal proliferation and growth, alveolar-lobular growth. Expansion of the glandular tissue results in invasion of adipose tissue, which progresses gradually, occurring simultaneous to increased vascularity and blood flow
- **Second half of pregnancy** hyperplasia, as well as the continuous involution of the fibrofatty stroma, colostrum accumulates in alveoli



As a result of these changes, the typical image of the breast at ultrasonography (US) is diffusely hypoechoic during pregnancy due to the increase in glandular tissue.

Chapter Outline

Breast Anatomy

Anatomical Variants

▶ **Pregnancy and Lactation**
▶ Pregnancy

Diagnostic Imaging Techniques

Disease of the Breast: Benign

Disease of the Breast: Malignant

Axilla

Interventional Procedures

Screening

High Risk Women

Communication

Multidisciplinary Team Meeting


Take-Home Messages

References

Test Your Knowledge



Post Partum



- At the end of the pregnancy high levels of oestrogens and progesterone counteract prolactin, this inhibiting milk production, although colostrum production occurs in the alveolar cells
- **After delivery:** The reduction in oestrogen and progesterone levels results in the continuous release of prolactin, by hypothalamus, and the physical stimulation of the nipple by the new-born suction promotes the release of oxytocin by the anterior pituitary gland, in order to stimulate and maintain lactation

Chapter Outline

Breast Anatomy

Anatomical Variants

▶ Pregnancy and Lactation
▶ Partum

Diagnostic Imaging Techniques

Disease of the Breast: Benign

Disease of the Breast: Malignant

Axilla

Interventional Procedures

Screening

High Risk Women

Communication

Multidisciplinary Team Meeting

Take-Home Messages

References

Test Your Knowledge



Partum



Lactogenesis => Conversion from a proliferative state during pregnancy to a secretory state during lactation.

- The amount of milk produced **does not** correlate with the amount of glandular tissue, the number of ducts, or the mean duct diameter.
- Immediate post-partum enlargement due to colostrum accumulation
- **3-7 days post partum** milk secreted into alveoli
- Post-lactational changes: periductal perivascular stromal connective tissue increases
- Alveolar cells and ductal branches regress



As a result of these changes, in ultrasonography (US) the typical image of the breast becomes diffusely hyperechoic during lactation, as a function of increased vascularity and prominence of the ducts.

Chapter Outline

Breast Anatomy

Anatomical Variants

▶ Pregnancy and Lactation
▶ Partum

Diagnostic Imaging Techniques

Disease of the Breast: Benign

Disease of the Breast: Malignant

Axilla

Interventional Procedures

Screening

High Risk Women

Communication

Multidisciplinary Team Meeting

Take-Home Messages

References

Test Your Knowledge



Lactation

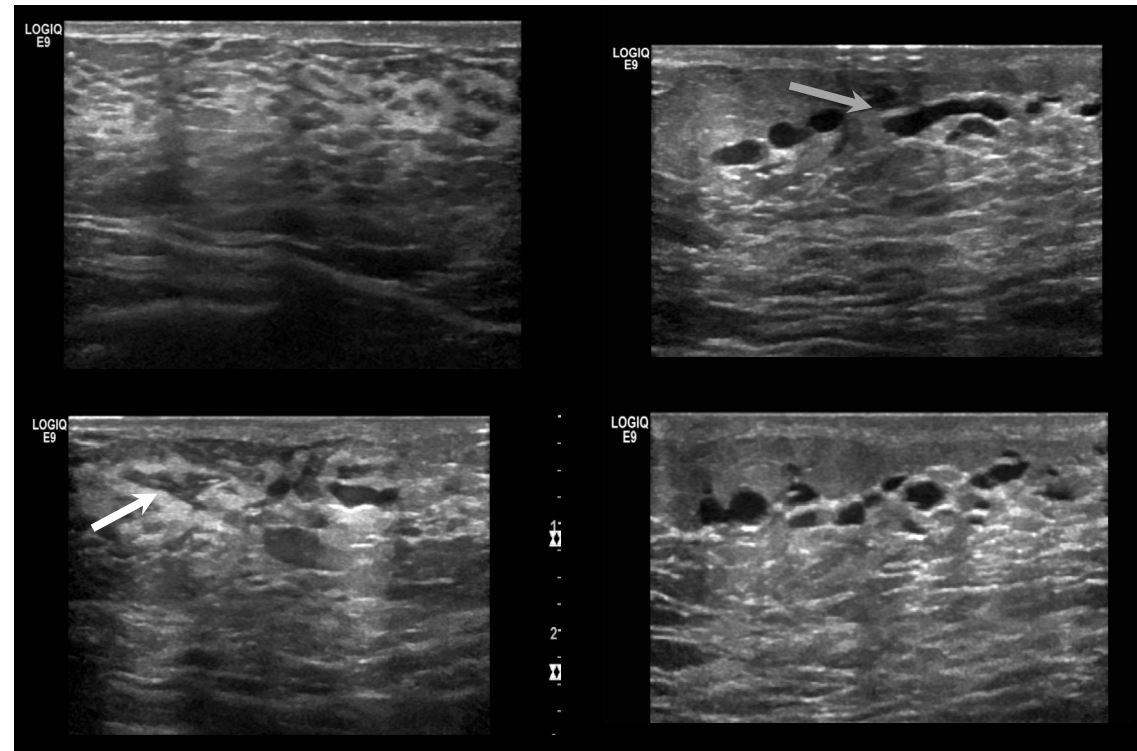


Mammographic findings (for screening wait 3 months after discontinuing lactation):

- Diffuse increase in size and density
- Little to no change to breast density

US Findings:

- Increase in parenchymal echogenicity
- Ductal ectasia
- Increased vascularity



Ultrasound of breastfeeding woman. The B-mode US shows increased echogenicity pattern of the fibroglandular tissue, with bilateral dilated ducts (black arrow). Some of them are filled with echogenic material (white arrow).

Chapter Outline

Breast Anatomy

Anatomical Variants

▶ Pregnancy and Lactation
▶ Lactation

Diagnostic Imaging Techniques

Disease of the Breast: Benign

Disease of the Breast: Malignant

Axilla

Interventional Procedures

Screening

High Risk Women

Communication

Multidisciplinary Team Meeting

Take-Home Messages

References

Test Your Knowledge



Diagnostic Imaging Techniques



- The most important diagnostic imaging techniques used in breast radiology/imaging are:
 - Mammography;
 - Digital Breast Tomosynthesis (DBT);
 - Ultrasound (US);
 - Magnetic Resonance Imaging (MRI);
 - Contrast-enhanced Mammography (CEM).

Chapter Outline

Breast Anatomy

Anatomical Variants

Pregnancy and Lactation

▶ Diagnostic Imaging Techniques

Disease of the Breast: Benign

Disease of the Breast: Malignant

Axilla

Interventional Procedures

Screening

High Risk Women

Communication

Multidisciplinary Team Meeting

Take-Home Messages

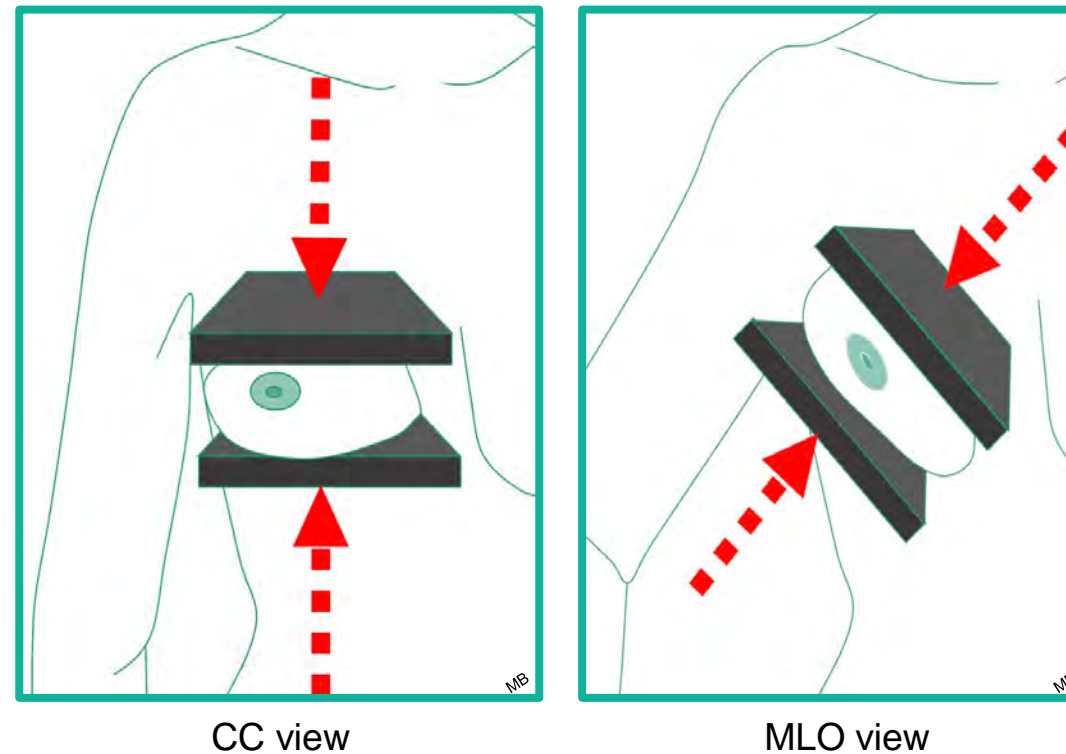
References

Test Your Knowledge

Mammography



- Mammography is a radiographic technique specifically designed for breast imaging.
- For the acquisition of mammograms – the images produced by Mammography –, the breast is compressed in order to allow the dispersion of its components and facilitate their visualization.
- The standard mammographic views are the craniocaudal (CC) and mediolateral oblique (MLO) views.



Orientation of the acquisition of the craniocaudal (CC) and mediolateral oblique (MLO) view.

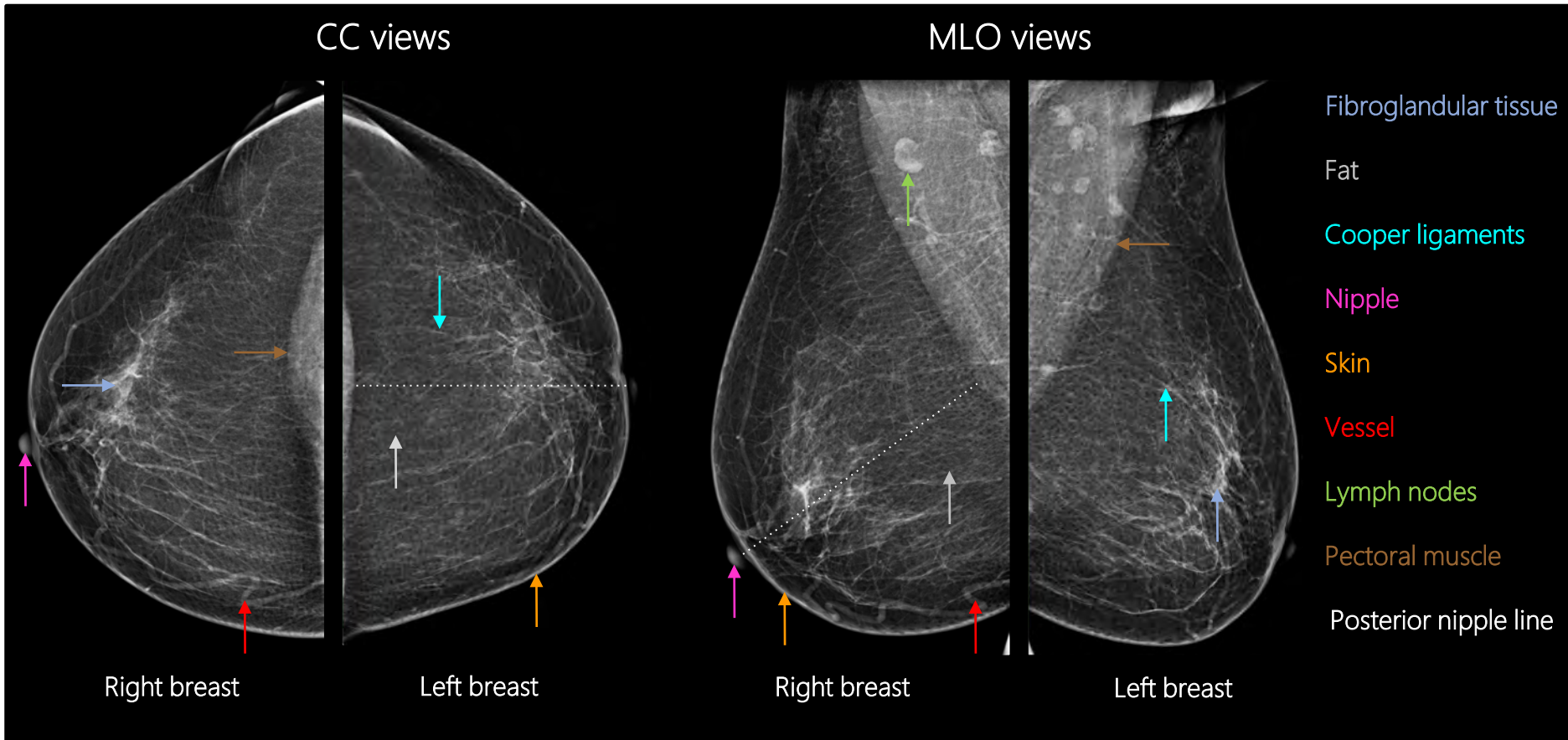
Chapter Outline

- Breast Anatomy
- Anatomical Variants
- Pregnancy and Lactation
- ▶ Diagnostic Imaging Techniques
 - ▶ Mammography
- Disease of the Breast: Benign
- Disease of the Breast: Malignant
- Axilla
- Interventional Procedures
- Screening
- High Risk Women
- Communication
- Multidisciplinary Team Meeting
- Take-Home Messages
- References
- Test Your Knowledge



Chapter Outline

- Breast Anatomy
- Anatomical Variants
- Pregnancy and Lactation
- ▶ Diagnostic Imaging Techniques
 - ▶ Mammography
- Disease of the Breast: Benign
- Disease of the Breast: Malignant
- Axilla
- Interventional Procedures
- Screening
- High Risk Women
- Communication
- Multidisciplinary Team Meeting
- Take-Home Messages
- References
- Test Your Knowledge



Breast anatomy as seen at normal mammography.



Mammography



Principles

- Quality criteria of adequate positioning for Mammography include:

- CC views:

- Well-visualized posterior medial breast;
- Pectoralis muscle should be demonstrated when possible;
- If the pectoralis muscle is not included, the length of the posterior nipple line (PNL) – an imaginary line extending posteriorly and perpendicularly from the nipple to the pectoralis muscle – on CC and MLO views should be within 1 cm of each other;
- Fat is seen posterior to the fibroglandular tissue;
- Nipple in profile.

- MLO views:

- Pectoralis muscle extends inferior to the PNL;
- Convex anterior border of the pectoralis muscle;
- Pectoralis muscle is wider superiorly and narrows inferiorly;
- Open inframammary fold;
- Fat is seen posterior to the fibroglandular tissue;
- Nipple in profile.

Chapter Outline

Breast Anatomy

Anatomical Variants

Pregnancy and Lactation

▶ **Diagnostic Imaging Techniques**
▶ Mammography

Disease of the Breast: Benign

Disease of the Breast: Malignant

Axilla

Interventional Procedures

Screening

High Risk Women

Communication

Multidisciplinary Team Meeting

Take-Home Messages

References

Test Your Knowledge



Mammography



- The **Average Glandular Dose (AGD)** = estimate of the average absorbed dose by the glandular breast tissue during Mammography measured in Gray (Gy):

$$AGD = K \times g \times c \times s$$

K: entrant surface air kerma

g: conversion factor for 50% glandular breast based on thickness and half-value layer

c: correction factor based on non-standard glandularity/thickness

s: correction factor based on non-molybdenum anode/filter combination

- AGD levels in Mammography are between 0,8 and 2,5 mGy for 4,5 cm PMMA (Polymethyl methacrylate) phantoms in clinical settings.
- AGD levels in Mammography increase with increased breast thickness
- Limiting AGD: 3-4 mGy.

Chapter Outline

Breast Anatomy

Anatomical Variants

Pregnancy and Lactation

▶ **Diagnostic Imaging Techniques**
▶ Mammography

Disease of the Breast: Benign

Disease of the Breast: Malignant

Axilla

Interventional Procedures

Screening

High Risk Women

Communication

Multidisciplinary Team Meeting

Take-Home Messages

References

Test Your Knowledge



Mammography



Main Indications

- *Screening Mammography:*
 - Applied on asymptomatic women to identify breast cancer at an early/ potentially curable stage;
 - Starting from the age of 45-50 to the age of 70-74 depending on the country.
- *Diagnostic Mammography:*
 - Applied on symptomatic patients or to work-up an abnormality found on Screening Mammography.
 - The standard mammographic views are supplemented with additional views (eg. lateral view, spot compression etc.) to further assess the screening-detected abnormality.

Chapter Outline

Breast Anatomy

Anatomical Variants

Pregnancy and Lactation

▶ Diagnostic Imaging Techniques
▶ Mammography

Disease of the Breast: Benign

Disease of the Breast: Malignant

Axilla

Interventional Procedures

Screening

High Risk Women

Communication

Multidisciplinary Team Meeting

Take-Home Messages

References

Test Your Knowledge

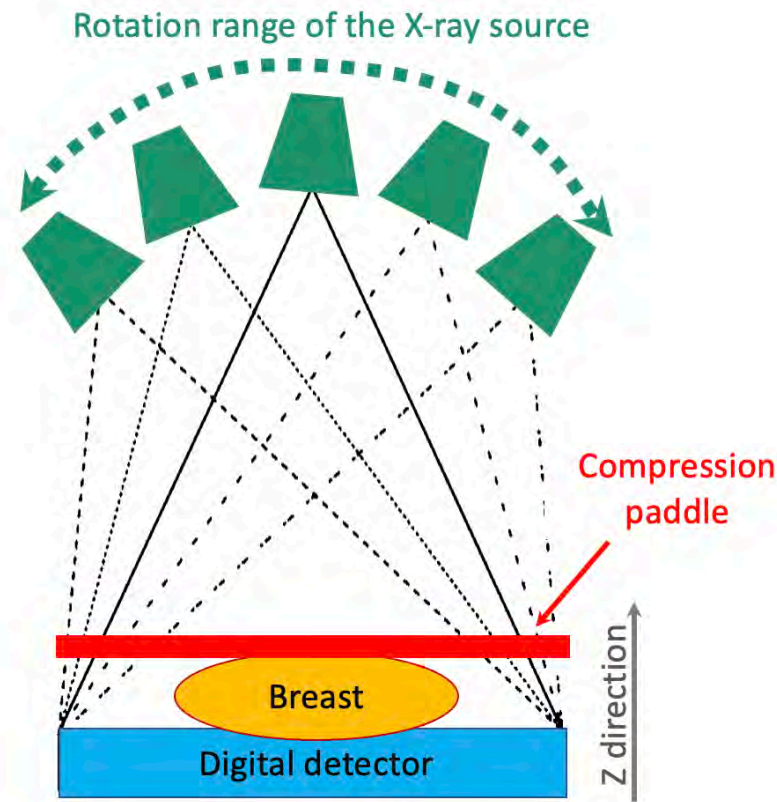


Digital Breast Tomosynthesis (DBT)



Principles/ Relative Diagnostic Value/ Main Indications

- DBT produces quasi-3D images of the breast based on the reconstruction of several low-dose 2D-projections acquired in a limited range of X-ray tube angles.
- It reduces the burden of overlapping tissues in the evaluation of standard mammography and improves the detection and the delineation of findings, increasing the sensitivity and the specificity/ decreasing the false negatives and the false positives
- It is particularly useful in the detection and delineation of masses and architectural distortions and in the further evaluation of asymmetries.



The X-ray source rotates around the compressed breast within a limited range (green dashed line). Projection images are formed on the detector. These are then reconstructed through the breast volume along the Z direction.

Chapter Outline

Breast Anatomy

Anatomical Variants

Pregnancy and Lactation

▶ Diagnostic Imaging Techniques
▶ DBT

Disease of the Breast: Benign

Disease of the Breast: Malignant

Axilla

Interventional Procedures

Screening

High Risk Women

Communication

Multidisciplinary Team Meeting

Take-Home Messages

References

Test Your Knowledge



Digital Breast Tomosynthesis (DBT)



Principles/ Relative Diagnostic Value

- DBT allows the production of *synthetic mammograms* – images similar in appearance to Digital Mammography (DM) that are generated based on the data acquired with DBT, without the need to further expose the breasts to additional radiation.
- DBT radiation dose depends on whether it includes additional Digital Mammography (DM) or synthetic mammograms.
- The radiation dose from DBT alone is currently similar or only slightly higher to that of DM

- DBT allows improved detection of architectural distortion in comparison to DM !



Chapter Outline

Breast Anatomy

Anatomical Variants

Pregnancy and Lactation

▶ Diagnostic Imaging Techniques
▶ DBT

Disease of the Breast: Benign

Disease of the Breast: Malignant

Axilla

Interventional Procedures

Screening

High Risk Women

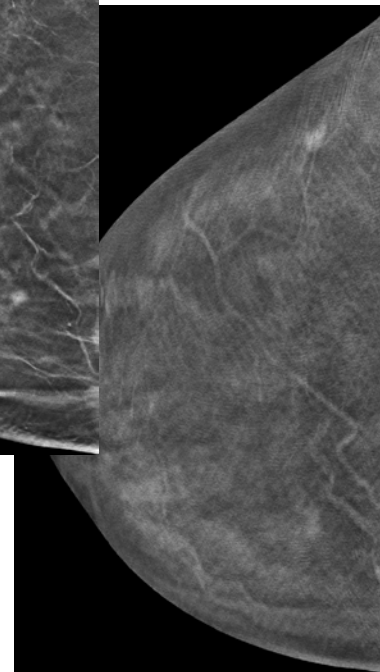
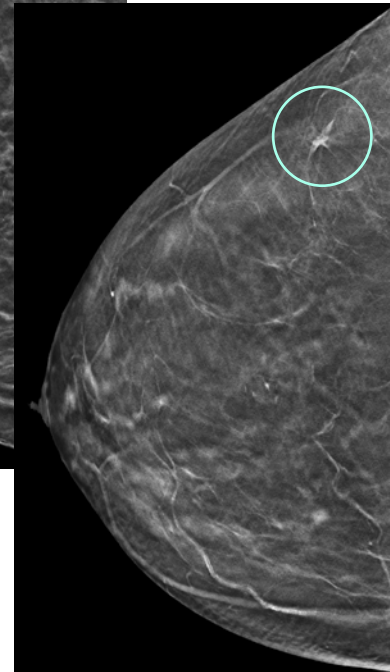
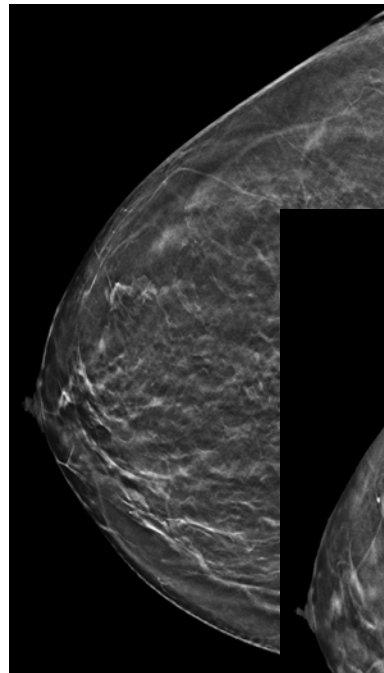
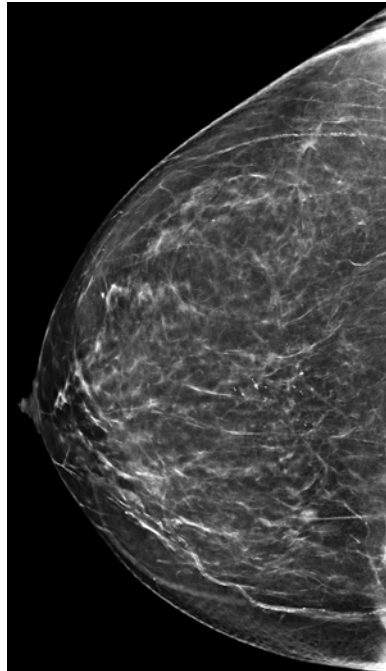
Communication

Multidisciplinary Team Meeting

Take-Home Messages

References

Test Your Knowledge



Chapter Outline

Breast Anatomy

Anatomical Variants

Pregnancy and Lactation

▶ Diagnostic Imaging Techniques
▶ DBT

Disease of the Breast: Benign

Disease of the Breast: Malignant

Axilla

Interventional Procedures

Screening

High Risk Women

Communication

Multidisciplinary Team Meeting

Take-Home Messages

References

Test Your Knowledge

Mammography vs DBT – CC views:

Improved detection and delineation of an architectural distortion in the upper outer quadrant of the right breast (Circle in DBT).



Digital Breast Tomosynthesis (DBT)



Chapter Outline

Breast Anatomy

Anatomical Variants

Pregnancy and Lactation

▶ Diagnostic Imaging Techniques
▶ DBT

Disease of the Breast: Benign

Disease of the Breast: Malignant

Axilla

Interventional Procedures

Screening

High Risk Women

Communication

Multidisciplinary Team Meeting

Take-Home Messages

References

Test Your Knowledge

Relative Diagnostic Value

- Main disadvantages compared to Mammography:
 - Longer evaluation time – approximately 2 times more;
 - Artifacts:
 - Blurring (continuous image acquisition);
 - Motion (longer scanning time).



Mammography and Digital Breast Tomosynthesis (DBT)



Principles

- **Breast density** refers to the relative amount of fibroglandular tissue comparing to fat in the breast.
- The 5th edition of **BI-RADS (Breast imaging-reporting and data system)** classifies breast density according to four descriptors (see also page 11):
 - **a:** The breasts are almost entirely fatty;
 - **b:** There are scattered areas of fibroglandular density;
 - **c:** The breasts are heterogeneously dense, which may obscure small masses;
 - **d:** The breasts are extremely dense, which lowers the sensitivity of Mammography.



Chapter Outline

[Breast Anatomy](#)

[Anatomical Variants](#)

[Pregnancy and Lactation](#)

▶ [Diagnostic Imaging Techniques](#)
▶ DBT

[Disease of the Breast: Benign](#)

[Disease of the Breast: Malignant](#)

[Axilla](#)

[Interventional Procedures](#)

[Screening](#)

[High Risk Women](#)

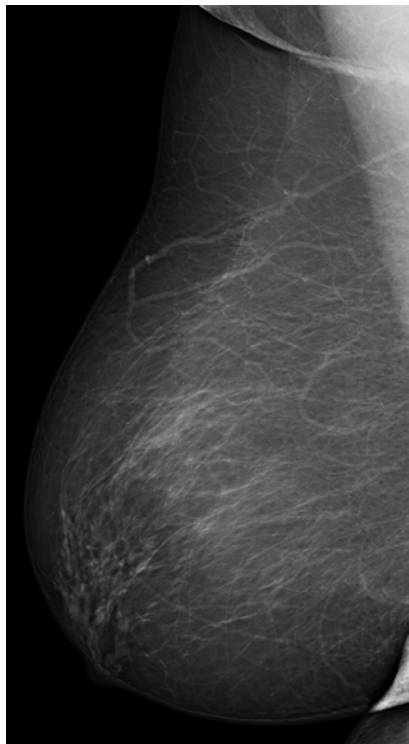
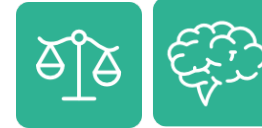[Communication](#)

[Multidisciplinary Team Meeting](#)

[Take-Home Messages](#)

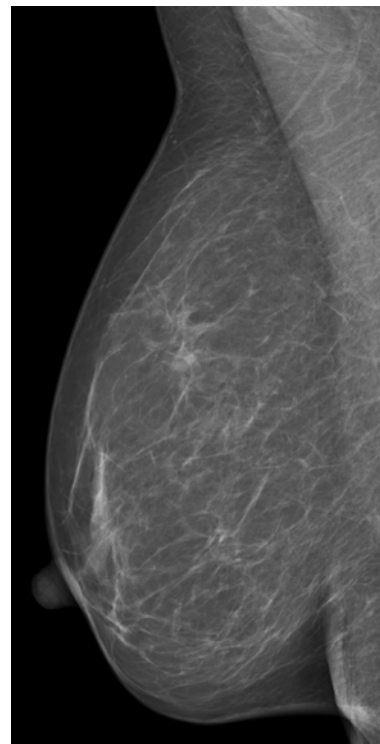
[References](#)

[Test Your Knowledge](#)



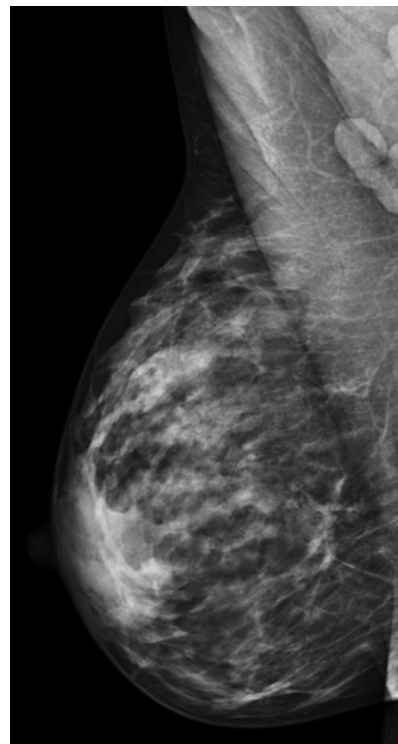
a

The breasts are almost entirely fatty



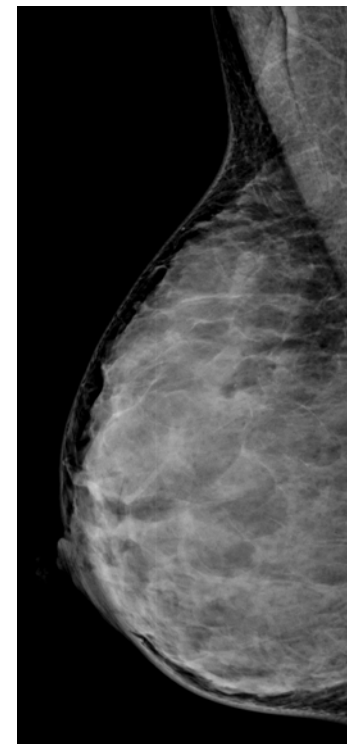
b

There are scattered areas of fibroglandular density



c

The breasts are heterogeneously dense, which may obscure small masses



d

The breasts are extremely dense, which lowers the sensitivity of Mammography

Breast density – Digital mammograms.

Chapter Outline

Breast Anatomy

Anatomical Variants

Pregnancy and Lactation

▶ Diagnostic Imaging Techniques
▶ DBT

Disease of the Breast: Benign

Disease of the Breast: Malignant

Axilla

Interventional Procedures

Screening

High Risk Women

Communication

Multidisciplinary Team Meeting

Take-Home Messages

References

Test Your Knowledge



Chapter Outline

Breast Anatomy

Anatomical Variants

Pregnancy and Lactation

▶ Diagnostic Imaging Techniques
▶ DBT

Disease of the Breast: Benign

Disease of the Breast: Malignant

Axilla

Interventional Procedures

Screening

High Risk Women

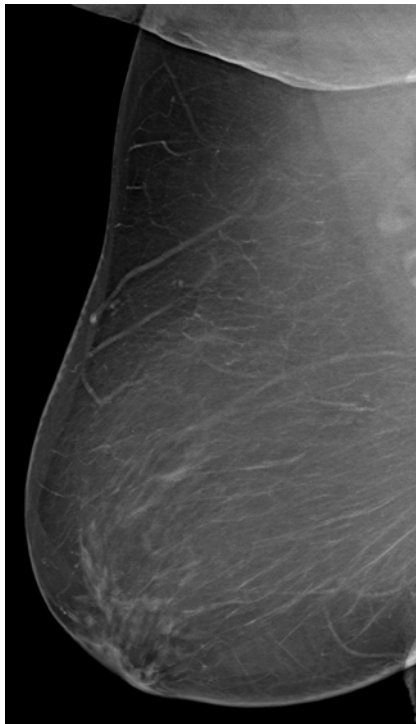
Communication

Multidisciplinary Team Meeting

Take-Home Messages

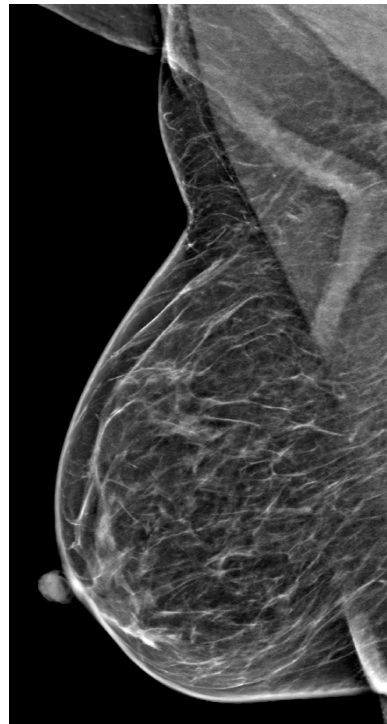
References

Test Your Knowledge



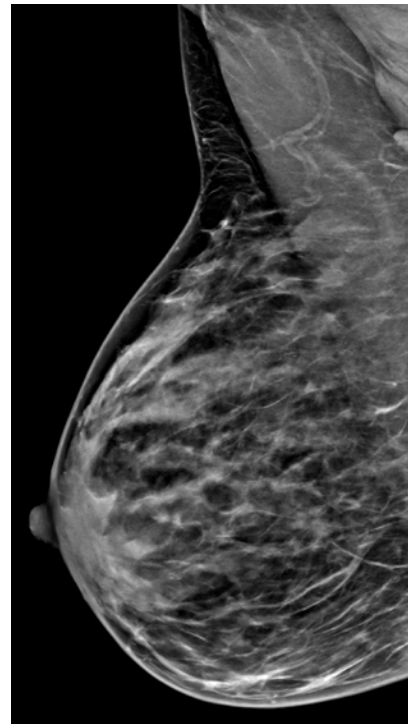
a

The breasts are almost entirely fatty



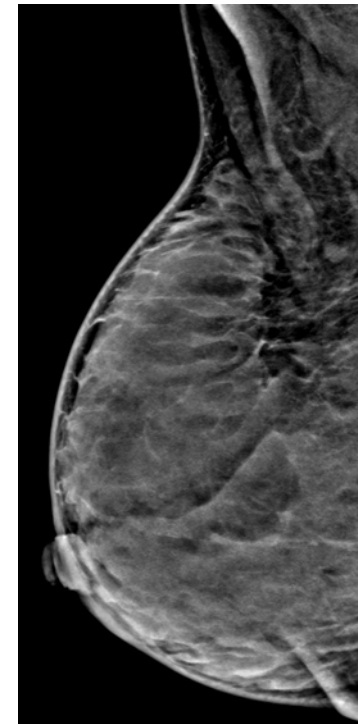
b

There are scattered areas of fibroglandular density



c

The breasts are heterogeneously dense, which may obscure small masses



d

The breasts are extremely dense, which lowers the sensitivity of Mammography

Breast density – Synthetic mammograms



Ultrasound (US)



Chapter Outline

Breast Anatomy

Anatomical Variants

Pregnancy and Lactation

▶ Diagnostic Imaging Techniques
▶ US

Disease of the Breast: Benign

Disease of the Breast: Malignant

Axilla

Interventional Procedures

Screening

High Risk Women

Communication

Multidisciplinary Team Meeting

Take-Home Messages

References

Test Your Knowledge

Breast US is an imaging technique that uses sound waves to visualize breast tissue:

- The US transducer sends ultrasound pulses and receives echoes that contain spatial and contrast information regarding the tissues that are being scanned.
- It is recommended using high-frequency transducers, with a broad bandwidth operating at a centre frequency of at least 12 MHz and preferably higher.

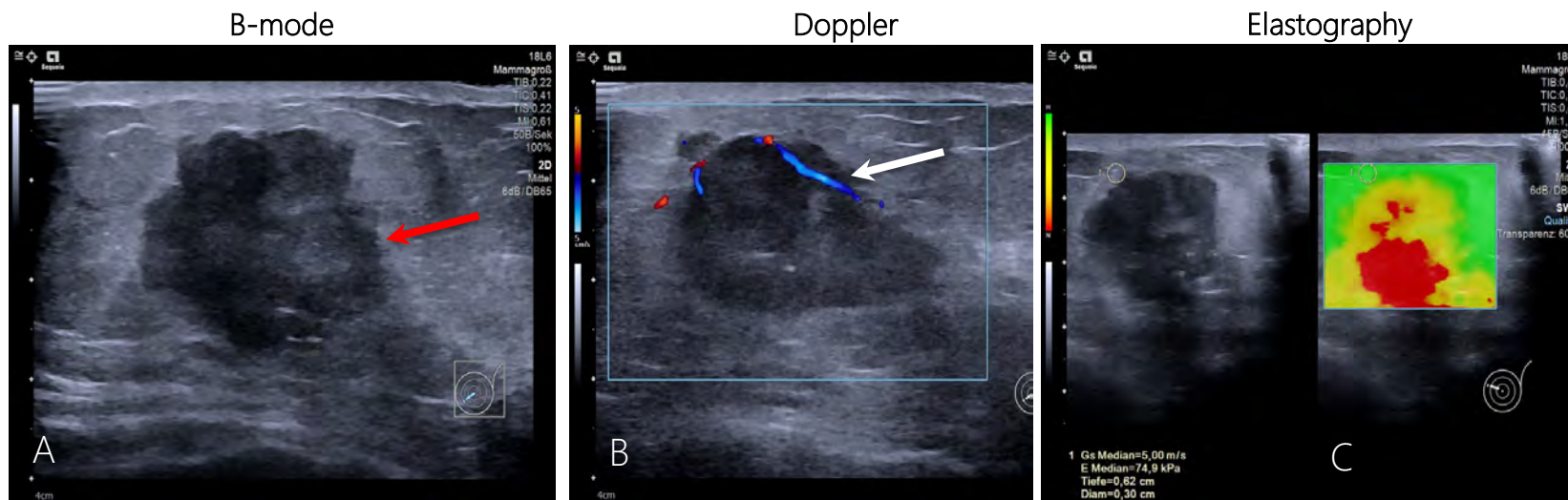


- See also [e book chapter](#) on ultrasound technique.

Ultrasound (US)



- Breast US modalities include:
 - B-mode (Grey-scale) – the standard modality;
 - Doppler – allows the evaluation of vascularization (e.g., simple cysts – absent vascularity vs solid lesions – present vascularity);
 - Elastography – allows the evaluation of stiffness (benign tumours – tend to be softer vs. malignant tumours – tend to be harder).



Breast US: B mode, Doppler and Elastography modalities revealing a biopsy-proven invasive breast cancer presenting as an irregular lesion (with microlobulated and angular margins, red arrow, A) heterogeneous hard mass exhibiting internal vascularity (white arrow, B) located in the inner quadrants of the left breast. Increased stiffness at elastography (C).

Chapter Outline

Breast Anatomy

Anatomical Variants

Pregnancy and Lactation

▶ Diagnostic Imaging Techniques
▶ US

Disease of the Breast: Benign

Disease of the Breast: Malignant

Axilla

Interventional Procedures

Screening

High Risk Women

Communication

Multidisciplinary Team Meeting

Take-Home Messages

References

Test Your Knowledge



Ultrasound (US)



Relative Diagnostic Value

- Main advantages:

- Non-ionizing radiation;
- More available;
- Less expensive.



- Main disadvantages:

- "Operator dependence";
- Longer scanning time.

Chapter Outline

Breast Anatomy

Anatomical Variants

Pregnancy and Lactation

▶ Diagnostic Imaging Techniques
▶ US

Disease of the Breast: Benign

Disease of the Breast: Malignant

Axilla

Interventional Procedures

Screening

High Risk Women

Communication

Multidisciplinary Team Meeting

Take-Home Messages

References

Test Your Knowledge



Ultrasound (US)



Main Indications

- Complementary assessment of findings detected by other imaging techniques (e.g., mammographically-detected masses and asymmetries, “second look” US after MRI)
- Evaluation of palpable abnormalities – direct real-time correlation of imaging and clinical findings:
 - Particularly in women with dense breasts (women with higher proportion of fibroglandular tissue) – Mammography is less sensitive.
- Evaluation of symptomatic young (usually <30 years of age) or lactating and pregnant women
- Guiding biopsies and other interventional procedures (e.g., aspiration of cysts, abscesses)

Chapter Outline

Breast Anatomy

Anatomical Variants

Pregnancy and Lactation

▶ Diagnostic Imaging Techniques
▶ US

Disease of the Breast: Benign

Disease of the Breast: Malignant

Axilla

Interventional Procedures

Screening

High Risk Women

Communication

Multidisciplinary Team Meeting

Take-Home Messages

References

Test Your Knowledge

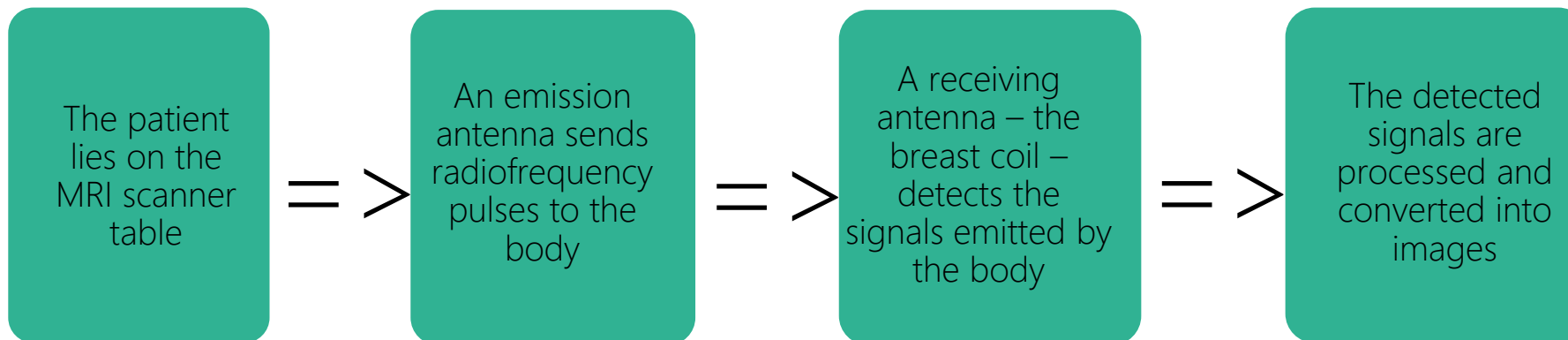


Magnetic Resonance Imaging (MRI)



Principles

- Breast MRI is an imaging technique that exploits the magnetism of the protons that constitute the breast (and surrounding) tissues to create diagnostic images:
 - In simple terms, breast MRI results from this sequence of events:



- See also [e book chapter on MRI technique](#)



Chapter Outline

Breast Anatomy

Anatomical Variants

Pregnancy and Lactation

▶ **Diagnostic Imaging Techniques**
▶ MRI

Disease of the Breast: Benign

Disease of the Breast: Malignant

Axilla

Interventional Procedures

Screening

High Risk Women

Communication

Multidisciplinary Team Meeting

Take-Home Messages

References

Test Your Knowledge



Magnetic Resonance Imaging (MRI)



The main sequences acquired in Breast MRI are:

- T1-weighted sequences (T1W) without and/or with fat saturation, the latter before and after intravenous administration of gadolinium-based contrast agent – dynamic contrast-enhanced (DCE) imaging; => Applications: Anatomy evaluation; DCE - Assessment of vascularization.
- T2-weighted sequences (T2W) without and/or with fat saturation => Applications: Detection of fluid (cysts, oedema.) – high signal intensity; Evaluation of the ductal system – normally high signal intensity.
- Diffusion-weighted imaging (DWI) => Applications: Further characterization of findings by evaluating the motion of water molecules in tissues - in highly cellular tissues (vs low cellular tissues), such as malignant lesions, there is restriction of the diffusion of water molecules, which is translated as a lower diffusion coefficient (*hindered diffusion*) in the image.

- See also [e book chapters on MRI and contrast media](#)



Chapter Outline

Breast Anatomy

Anatomical Variants

Pregnancy and Lactation

▶ Diagnostic Imaging Techniques
▶ MRI

Disease of the Breast: Benign

Disease of the Breast: Malignant

Axilla

Interventional Procedures

Screening

High Risk Women

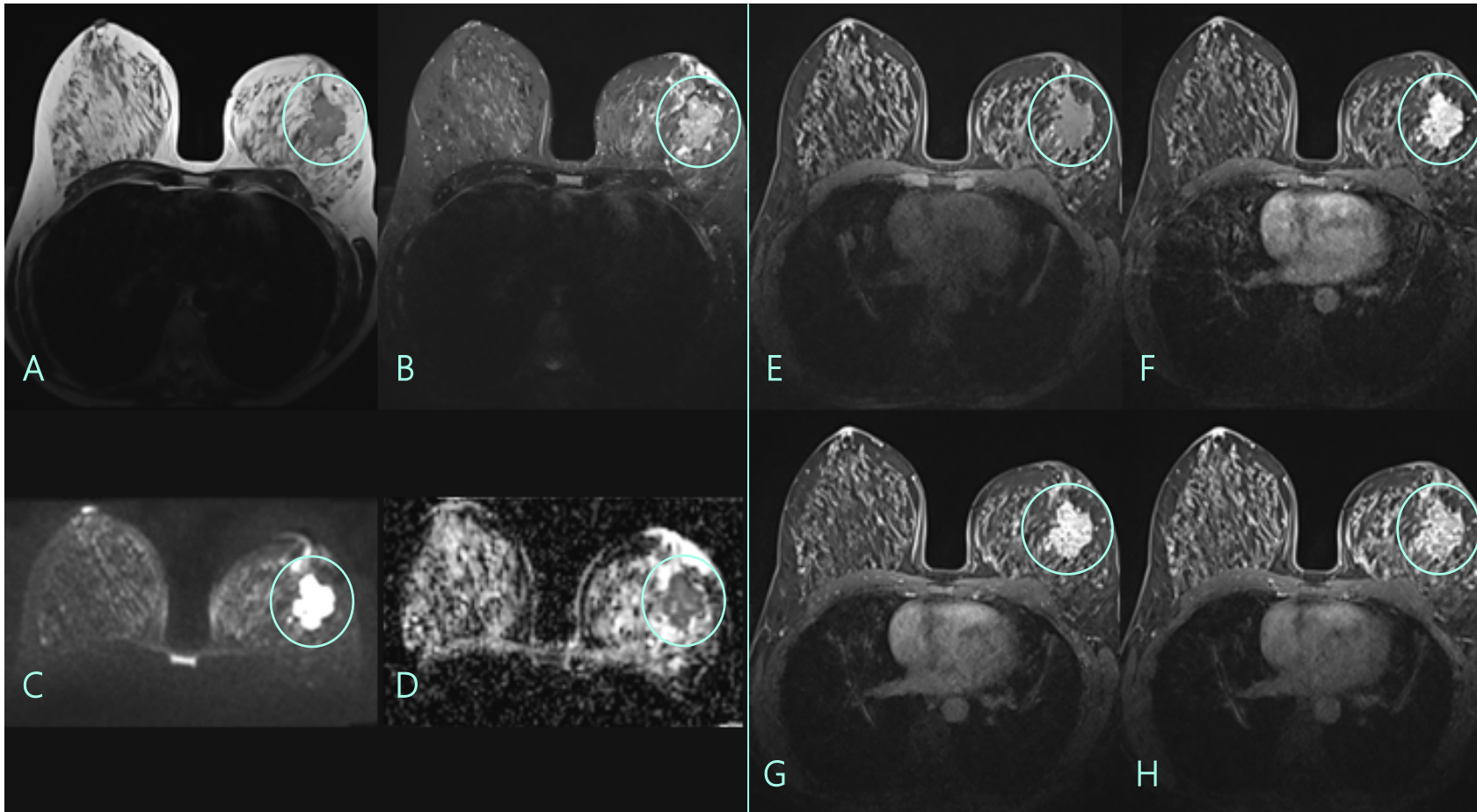
Communication

Multidisciplinary Team Meeting

Take-Home Messages

References

Test Your Knowledge



Breast MRI: T2-weighted sequences – without (A) and with (B) fat saturation –, Diffusion-weighted imaging (C) with apparent diffusion coefficient (ADC) map (D) and T1-weighted sequences with fat saturation before (E) and after (F-H) intravenous administration of gadolinium-based contrast agent showing a biopsy-proven invasive breast cancer presenting as a mass with irregular margins located in the outer left breast quadrants (green circle) with heterogeneous internal enhancement (H) and perilesional oedema (B)..



Chapter Outline

- Breast Anatomy
- Anatomical Variants
- Pregnancy and Lactation
- ▶ Diagnostic Imaging Techniques
 - ▶ MRI
- Disease of the Breast: Benign
- Disease of the Breast: Malignant
- Axilla
- Interventional Procedures
- Screening
- High Risk Women
- Communication
- Multidisciplinary Team Meeting
- Take-Home Messages
- References
- Test Your Knowledge



Magnetic Resonance Imaging (MRI)



Relative Diagnostic Value

- Main advantages:
 - Non-ionizing radiation
 - High sensitivity (up to 99%)
 - Superior soft-tissue contrast
 - Further characterization of breast lesions by using morphological and functional information (DCE and DWI)



- Main disadvantages:
 - Less available
 - More expensive
 - Longer scanning times – motion artifacts
 - Limited use in certain circumstances – e.g., claustrophobia and certain metallic devices

Chapter Outline

Breast Anatomy

Anatomical Variants

Pregnancy and Lactation

▶ **Diagnostic Imaging Techniques**
▶ MRI

Disease of the Breast: Benign

Disease of the Breast: Malignant

Axilla

Interventional Procedures

Screening

High Risk Women

Communication

Multidisciplinary Team Meeting

Take-Home Messages

References

Test Your Knowledge



Magnetic Resonance Imaging (MRI)



Main Indications

- Breast cancer staging;
- Evaluation of response to neoadjuvant therapy;
- "Problem solving" (eg. Unclear findings in Digital Mammography, DBT and US; evaluation of suspicious nipple discharge);
- High-risk screening (eg. BRCA1 and BRCA2 mutations carriers);
- Screening of women with extremely dense breasts;
- Carcinoma of unknown primary (CUP) syndrome
- Evaluation of breast implants.

Chapter Outline

Breast Anatomy

Anatomical Variants

Pregnancy and Lactation

▶ Diagnostic Imaging Techniques
▶ MRI

Disease of the Breast: Benign

Disease of the Breast: Malignant

Axilla

Interventional Procedures

Screening

High Risk Women

Communication

Multidisciplinary Team Meeting

Take-Home Messages

References

Test Your Knowledge



Contrast-Enhanced Mammography (CEM)



Principles

CEM is an imaging technique based on dual-energy mammographic acquisition after intravenous administration of an iodinated contrast agent; it highlights areas of increased contrast agent uptake:

Typically, 90-150 mL of an iodinated contrast agent is administered via a cannula placed in the antecubital fossa, followed by administration of 20 ml of saline solution at the same rate.

At least 90 seconds after the administration of the contrast agent, two images are produced for each compression/view:

- A **low energy image** (below the k-edge of iodine) – equivalent to a standard Digital Mammogram;
- A **high energy image** (above the k-edge of iodine) and resulting *recombined image* – the background breast tissue is suppressed to highlight areas of increased contrast agent uptake.

Chapter Outline

Breast Anatomy

Anatomical Variants

Pregnancy and Lactation

▶ Diagnostic Imaging Techniques
▶ CEM

Disease of the Breast: Benign

Disease of the Breast: Malignant

Axilla

Interventional Procedures

Screening

High Risk Women

Communication

Multidisciplinary Team Meeting

Take-Home Messages

References

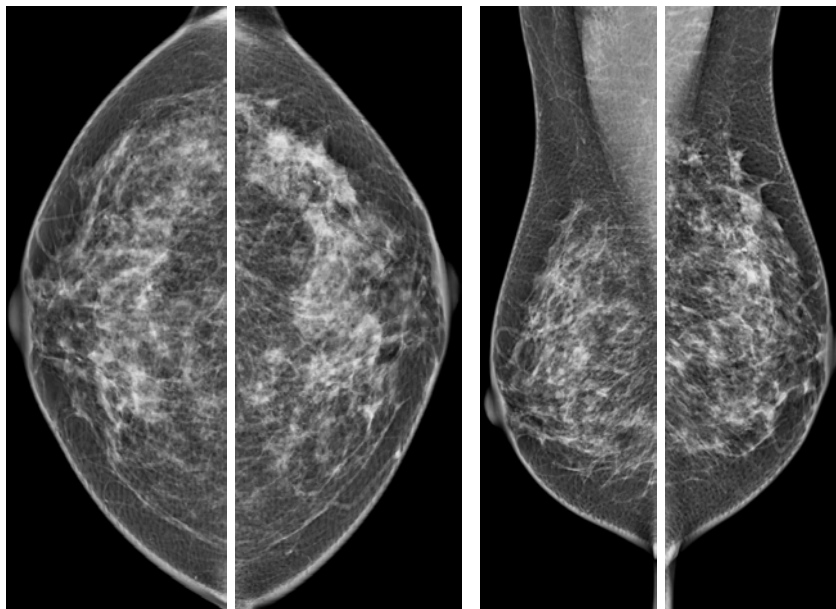
Test Your Knowledge



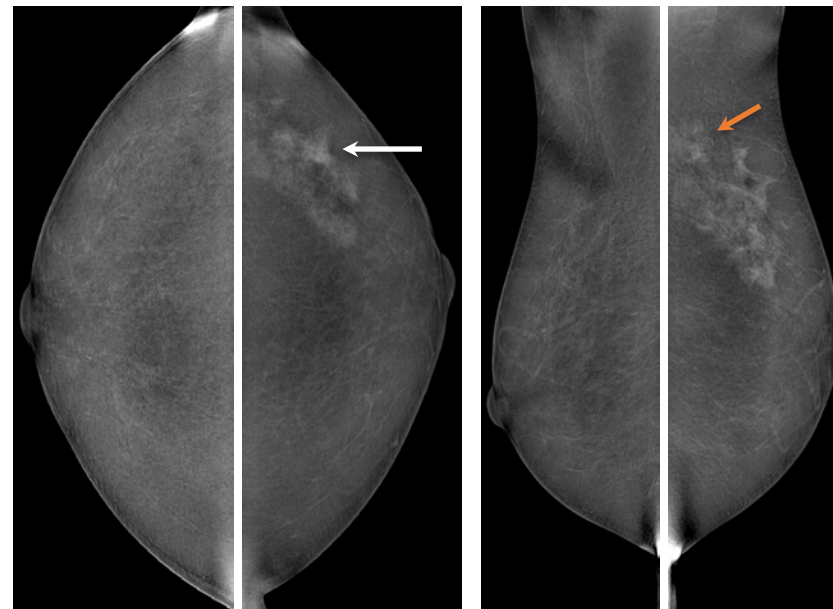
Chapter Outline

- Breast Anatomy
- Anatomical Variants
- Pregnancy and Lactation
- ▶ Diagnostic Imaging Techniques
 - ▶ CEM
- Disease of the Breast: Benign
- Disease of the Breast: Malignant
- Axilla
- Interventional Procedures
- Screening
- High Risk Women
- Communication
- Multidisciplinary Team Meeting
- Take-Home Messages
- References
- Test Your Knowledge

Low energy images



Recombined images



CEM: Low energy images show segmental pleomorphic microcalcifications in the upper outer quadrant of the left breast – further stereotactic-guided biopsy revealed Ductal Carcinoma *in situ* (DCIS); *recombined images* show coexistent but more extensive segmental clumped non-mass enhancement (white arrow), reaching the axillary tail (orange arrow).



Contrast-Enhanced Mammography (CEM)



Relative Diagnostic Value

- CEM is more sensitive and specific than standard Digital Mammography due to the vascularity assessment.
- Studies comparing CEM and Breast MRI have found similar sensitivities but variable specificities.

Main advantages compared to breast MRI:

- Lower cost
- Shorter scanning times



Main disadvantages compared to breast MRI:

- Limited *Field of View (FoV)* – cannot assess most of the axilla or chest wall
- Ionizing radiation
- More adverse reactions to iodinated contrast agents

Chapter Outline

Breast Anatomy

Anatomical Variants

Pregnancy and Lactation

▶ Diagnostic Imaging Techniques
▶ CEM

Disease of the Breast: Benign

Disease of the Breast: Malignant

Axilla

Interventional Procedures

Screening

High Risk Women

Communication

Multidisciplinary Team Meeting

Take-Home Messages

References

Test Your Knowledge



Contrast-Enhanced Mammography (CEM)



Relative Diagnostic Value/ Main Indications

- The EUSOBI recommendations state that CEM can be considered as an alternative to Breast MRI for women with contraindications (eg. claustrophobia, metallic devices):
 - Although investigation on Indications is still ongoing, they are generically similar to those of Breast MRI:
 - Breast cancer staging
 - Evaluation of response to neoadjuvant therapy
 - "Problem solving"

Chapter Outline

Breast Anatomy

Anatomical Variants

Pregnancy and Lactation

▶ Diagnostic Imaging Techniques
▶ CEM

Disease of the Breast: Benign

Disease of the Breast: Malignant

Axilla

Interventional Procedures

Screening

High Risk Women

Communication

Multidisciplinary Team Meeting

Take-Home Messages

References

Test Your Knowledge



Benign Breast Diseases: Cysts



- Cysts are fluid-filled round or oval masses lined by epithelium
- **Most common mass in female breast**, Can occur at any age; peak prevalence: 35-50 years
- Patient can feel generalized or focal tenderness/pain (↑ during premenstrual phase of cycle)
- Can be anywhere in breast, but very rare in the axilla
- Simple cysts have no malignant potential

Complicated breast cyst: contains intracystic echoes or debris with other features of a simple cyst

Complex breast cyst ("solid and cystic mass"): thick walled with thick septa or an intracystic solid mass, can have a malignant potential!



Cyst is the most common mass in the female breast.

Chapter Outline

Breast Anatomy

Anatomical Variants

Pregnancy and Lactation

Diagnostic Imaging Techniques

▶ **Disease of the Breast: Benign**
▶ Cysts

Disease of the Breast: Malignant

Axilla

Interventional Procedures

Screening

High Risk Women

Communication

Multidisciplinary Team Meeting

Take-Home Messages

References

Test Your Knowledge

Cysts – Imaging



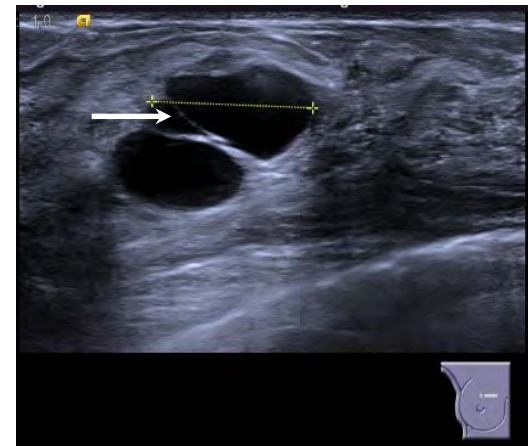
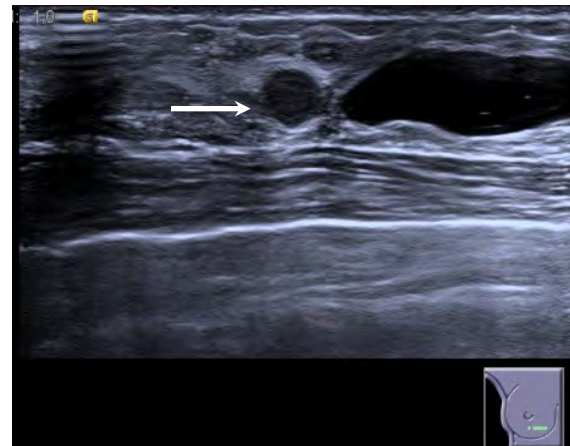
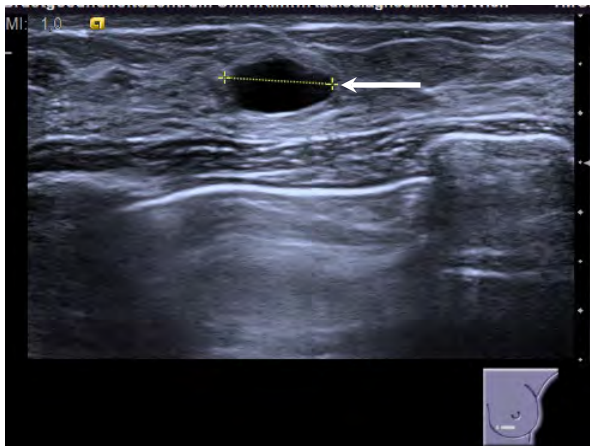
Best diagnostic tool is **ultrasound (US)**.

- Circumscribed, oval or round, anechoic mass with imperceptible wall and posterior enhancement
- Can be deformable with transducer compression (not observed with solid masses)
- Power or color Doppler => Absent flow: Internal vascularity excludes simple cyst



US-guided fine-needle aspiration (FNA) is only useful in case of symptoms/signs of inflammation to reduce the symptoms as cysts can recur.

If a solid component is suspected, than prefer MRI and/or biopsy (core needle or vacuum assisted)



(Left) Ultrasound in a 35-year-old woman demonstrates an oval, circumscribed, anechoic mass with posterior enhancement (i.e., a simple cyst) in the left breast (left). Same patient has group of cysts with lobulated margin with debris (middle) and thin septations (right) in the right breast.

Chapter Outline

Breast Anatomy

Anatomical Variants

Pregnancy and Lactation

Diagnostic Imaging Techniques

▶ Disease of the Breast: Benign
▶ Cysts

Disease of the Breast: Malignant

Axilla

Interventional Procedures

Screening

High Risk Women

Communication

Multidisciplinary Team Meeting

Take-Home Messages

References

Test Your Knowledge



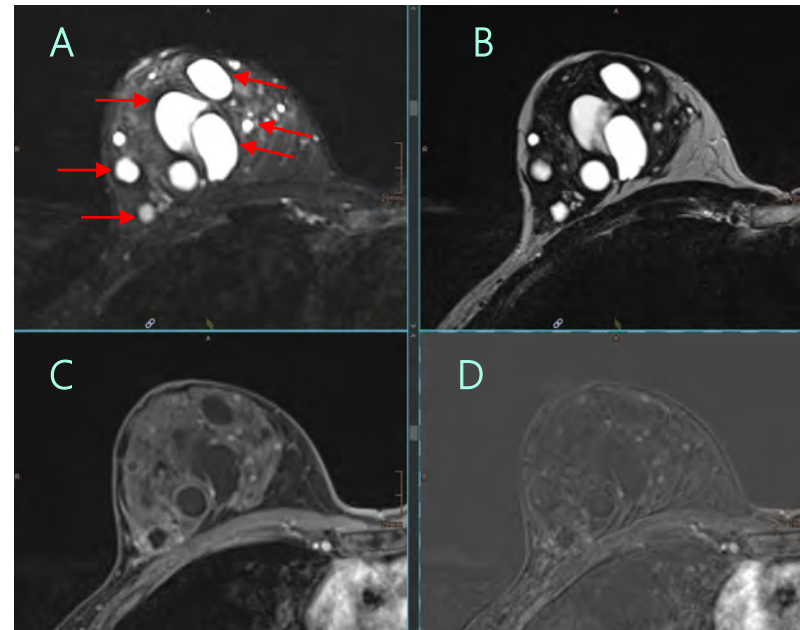
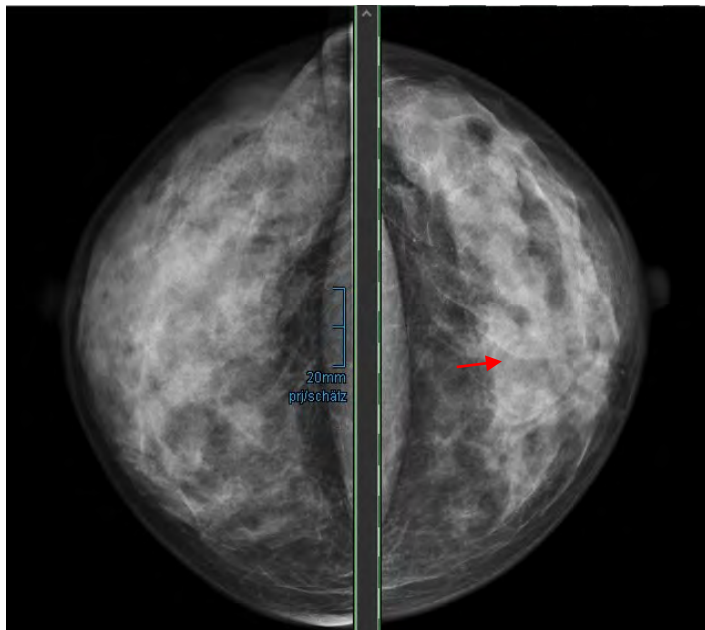
Cysts – Imaging



Mammography findings: Oval or round shaped, circumscribed or partially obscured mass. The density is lower or equal to breast parenchyma.

MRI Findings:

- T1W: Circumscribed, round or oval mass; low signal intensity (may have high signal if complicated)
- STIR: Homogeneously hyperintense, proteinaceous content → lower signal intensity
- T1W post-Gd: No enhancement; imperceptible wall



(Left) A 42-year-old woman noted a lump in her upper inner left breast. On CC mammogram, the palpable finding was seen to correspond a large, partly obscured mass (arrow).

(Right) Axial STIR MR (A) (another patient) shows multiple (arrows), circumscribed, T2-hyperintense (B) oval masses due to simple cysts ft. Axial T1 C+ FS (C) and subtraction (D) MR shows nonenhancing cysts.

Chapter Outline

Breast Anatomy

Anatomical Variants

Pregnancy and Lactation

Diagnostic Imaging Techniques

▶ Disease of the Breast: Benign
▶ Cysts

Disease of the Breast: Malignant

Axilla

Interventional Procedures

Screening

High Risk Women

Communication

Multidisciplinary Team Meeting

Take-Home Messages

References

Test Your Knowledge



Fibrocystic Changes



The term **fibrocystic changes (FCC)** indicates a spectrum of histopathologic benign changes of the female mammary gland including cysts, fibrosis, apocrine metaplasia, calcifications, inflammation, epithelial hyperplasia, and sclerosing adenosis (SA). FCC is **not as a disease but rather** a disorder of physiological development, maturation, and involution.

Most common symptom is **mastalgia** – focal or diffuse, particularly outer breasts, changes with menstrual cycle, more commonly in women with high amount of fibroglandular tissue

More common in premenopausal women, trend to increase with nulliparity, and later menopause

Fibrocystic changes can be **proliferative** or **non-proliferative**.

- **Nonproliferative FCC:** Periductal fibrosis, cysts, nonsclerosing adenosis) are the most common findings in breast biopsies (70% of all cases). No increased risk of carcinoma.
- **Proliferative FCC:** Intraductal hyperplasia, sclerosing adenosis, radial scars, and papillomas are associated with a relatively increased risk of developing carcinoma in either breast (1.5-2.0x)



Chapter Outline

Breast Anatomy

Anatomical Variants

Pregnancy and Lactation

Diagnostic Imaging Techniques

▶ Disease of the Breast: Benign
▶ Fibrocystic Changes

Disease of the Breast: Malignant

Axilla

Interventional Procedures

Screening

High Risk Women

Communication

Multidisciplinary Team Meeting

Take-Home Messages

References

Test Your Knowledge



Fibroadenoma



Fibroadenoma (FA) is a common benign breast lesion resulting from excess proliferation of connective tissue. Fibroadenomas characteristically contain both stromal and epithelial cells.

- Most common solid mass in women of all ages (peak incidence 25-30 years)
- Most common sign: mobile, non-adherent palpable mass ±> tender
- Adult and juvenile ("cellular") types
- Natural history of FA to become sclerosed and calcify, involute spontaneously following menopause
- Follow-up to document possible growth is required, if the lesion diameter increases by **more than 20 percent** within 6 months and/or develops **suspicious features**, biopsy is recommended. If the biopsy result is equivocal or discordant, surgical excision is indicated.



Fibroadenoma is the most common solid mass in women

Chapter Outline

Breast Anatomy

Anatomical Variants

Pregnancy and Lactation

Diagnostic Imaging Techniques

▶ Disease of the Breast: Benign
▶ Fibroadenoma

Disease of the Breast: Malignant

Axilla

Interventional Procedures

Screening

High Risk Women

Communication

Multidisciplinary Team Meeting

Take-Home Messages

References

Test Your Knowledge



Fibroadenoma – Imaging



Best tool for initial imaging => ultrasound if <40y and mammography if > 40y, followed by US if needed.



Mammography :

- Oval or macrolobulated, **circumscribed** (can present a halo sign)
- Multiplicity/bilaterality may be more evident on DBT
- Can have calcifications (**popcorn-shaped**), very dense or large; heterogeneous calcifications often gradually ↑ and coarsen as FA involutes



US :

- Circumscribed, oval or gently lobulated, slightly hypo- to isoechoic mass with the long axis **parallel** to skin surface & the length:height ratio typically > 1.4 (mean: 1.8)
- Homogeneous, low-level internal echogenicity & echogenic calcifications ± shadowing
- Doppler: Peripheral and feeding vessels common in juvenile fibroadenomas



MRI :

- T2WI/STIR: Myxoid FA and FA in young women usually ↑ T2 signal; After menopause, sclerosis and hyalinization → ↓ T2 signal
- DWI: Often bright with unhindered diffusion (high ADC)
- Contrast enhanced T1WI : Oval or macrolobulated, circumscribed, enhancing mass



PET CT:

- Common false-positive as most often FDG avid in Positron Emission Tomography.



Chapter Outline

Breast Anatomy

Anatomical Variants

Pregnancy and Lactation

Diagnostic Imaging Techniques

▶ Disease of the Breast: Benign
▶ Fibroadenoma

Disease of the Breast: Malignant

Axilla

Interventional Procedures

Screening

High Risk Women

Communication

Multidisciplinary Team Meeting

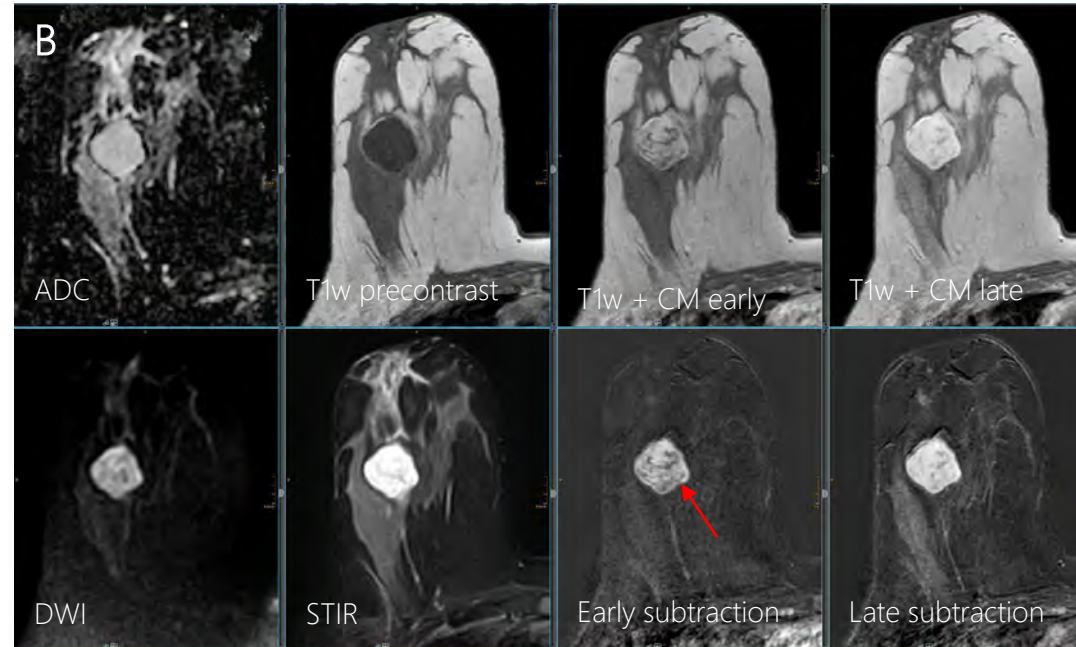
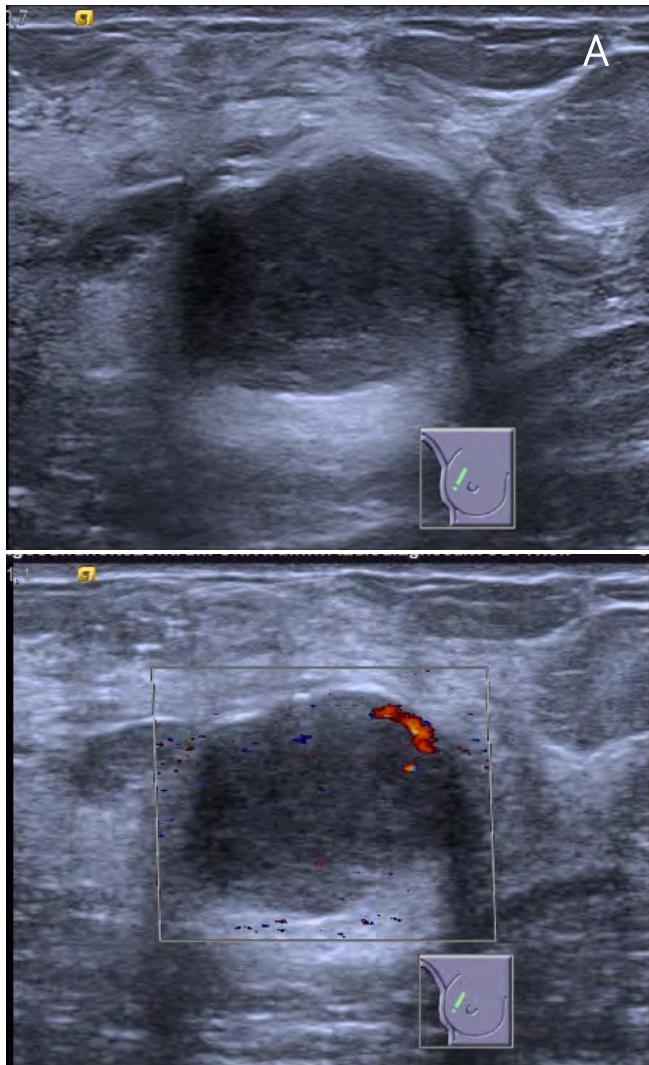
Take-Home Messages

References

Test Your Knowledge



Fibroadenoma – Imaging



(A) 9-year old woman had a palpable lump in upper outer right breast. Targeted US show a slightly lobulated, oval mass with mild posterior enhancement. Doppler US shows peripheral vascularisation.

(B) Representative axial multiparametric MRI of the right breast (same patient) shows large, enhancing (persistent signal increase), circumscribed, oval mass with dark internal septations (**arrow**).

Chapter Outline

- Breast Anatomy
- Anatomical Variants
- Pregnancy and Lactation
- Diagnostic Imaging Techniques
- ▶ Disease of the Breast: Benign
 - ▶ Fibroadenoma
- Disease of the Breast: Malignant
- Axilla
- Interventional Procedures
- Screening
- High Risk Women
- Communication
- Multidisciplinary Team Meeting
- Take-Home Messages
- References
- Test Your Knowledge



Phylloides Tumour

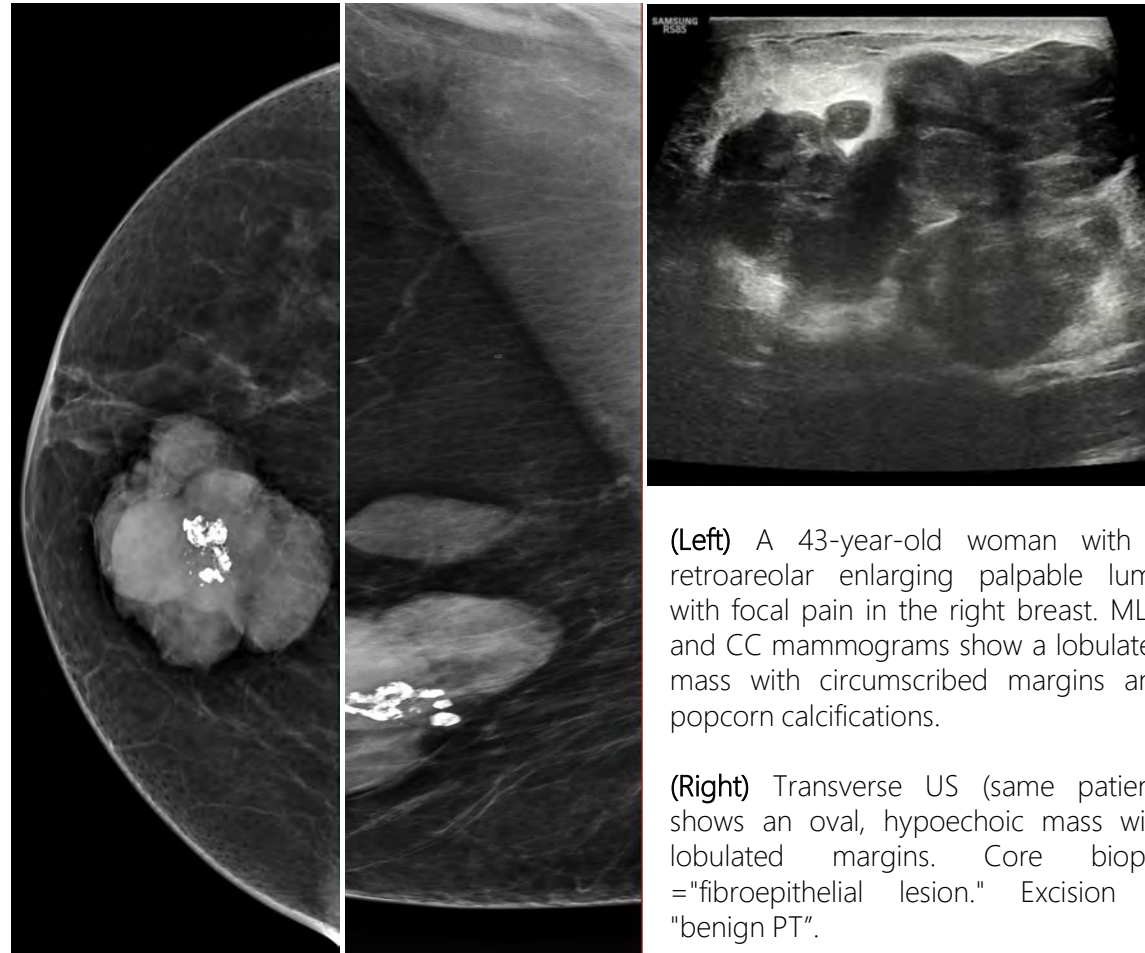


Phyllodes tumour is a rare fibroepithelial tumour of the breast which resembles fibroadenoma.

It is typically a **large, fast growing** mass (3-5 cm at presentation) that forms from the periductal stroma of the breast.

Pathological distinction between fibroadenoma and phyllodes tumour is based on cellularity and overgrowth of stroma, margins, and mitotic figures.

- Imaging **cannot** reliably distinguish fibroadenoma from benign phylloides tumour.
- Complete surgical excision is curative with wide local excision



(Left) A 43-year-old woman with a retroareolar enlarging palpable lump with focal pain in the right breast. MLO and CC mammograms show a lobulated mass with circumscribed margins and popcorn calcifications.

(Right) Transverse US (same patient) shows an oval, hypoechoic mass with lobulated margins. Core biopsy = "fibroepithelial lesion." Excision = "benign PT".

Chapter Outline

Breast Anatomy

Anatomical Variants

Pregnancy and Lactation

Diagnostic Imaging Techniques

▶ Disease of the Breast: Benign
▶ Phylloides Tumour

Disease of the Breast: Malignant

Axilla

Interventional Procedures

Screening

High Risk Women

Communication

Multidisciplinary Team Meeting

Take-Home Messages

References

Test Your Knowledge



Hamartoma



Hamartoma, also known as fibroadenolipoma, is a **focal developmental malformation**. Usually circumscribed lesion with abnormal mixture of tissue elements or abnormal proportion of single element.

- Disorganized overgrowth of benign mammary tissue with normal differentiation of cells; variously ductal, lobular epithelium; stromal mesenchymal elements “breast within a breast”
- Type of biphasic breast lesion : contains integral epithelial and stromal components
- Typically benign finding, BI-RADS 2
- Core biopsy: Rarely indicated
- Usually asymptomatic, found on screening; can present as vague breast mass, can enlarge



Chapter Outline

Breast Anatomy

Anatomical Variants

Pregnancy and Lactation

Diagnostic Imaging Techniques

▶ **Disease of the Breast: Benign**
▶ Hamartoma

Disease of the Breast: Malignant

Axilla

Interventional Procedures

Screening

High Risk Women

Communication

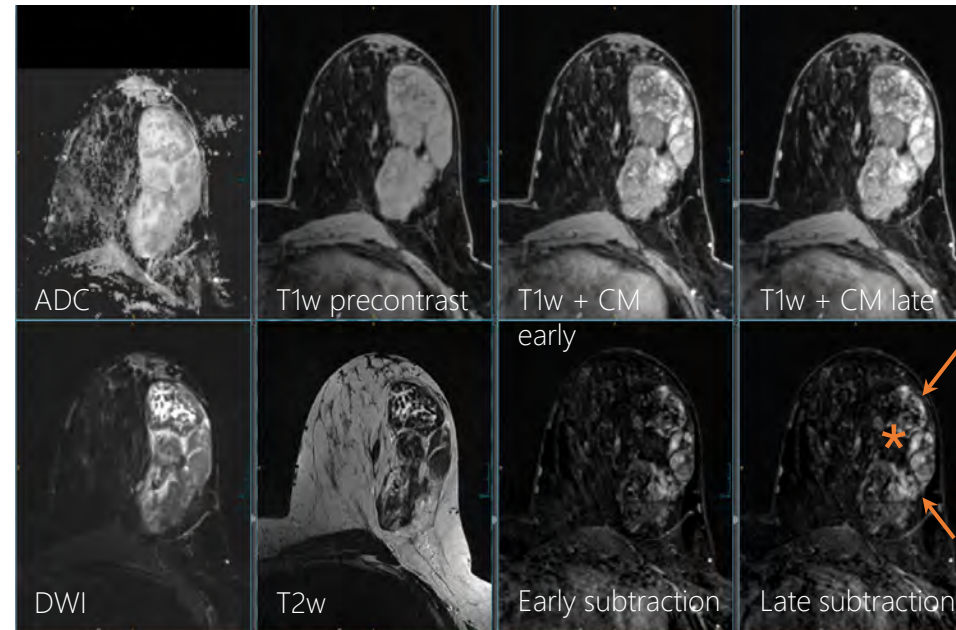
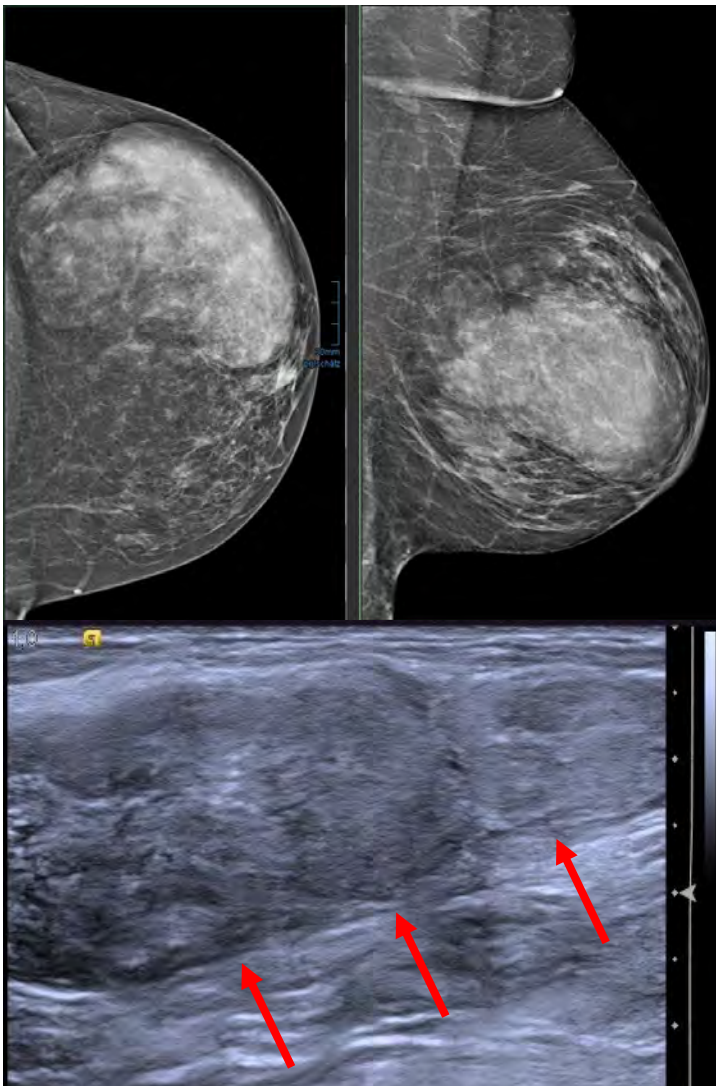
Multidisciplinary Team Meeting

Take-Home Messages

References

Test Your Knowledge

Hamartoma – Imaging



(Left) CC and MLO mammogram in a 41-year-old woman with asymmetric left breast shows a superficial 10-cm, oval, circumscribed mass. The mass is composed of mixed fat and fibroglandular elements surrounded by a pseudocapsule, consistent with hamartoma. US (same patient) shows a corresponding isoechoic oval mass with pseudocapsule (arrows). (Right) T1 C+ FS MR (same patient) performed to evaluate right breast mass shows a circumscribed, oval mass with persistent enhancing fibroglandular elements (arrow) and nonenhancing fat (asterisk).

Chapter Outline

Breast Anatomy

Anatomical Variants

Pregnancy and Lactation

Diagnostic Imaging Techniques

▶ Disease of the Breast: Benign
▶ Hamartoma

Disease of the Breast: Malignant

Axilla

Interventional Procedures

Screening

High Risk Women

Communication

Multidisciplinary Team Meeting

Take-Home Messages

References

Test Your Knowledge



Lipoma and Angiolipoma



Lipoma is a benign neoplasm composed of mature adipose cells.

Angiolipoma is a benign fatty neoplasm with capillary networks and fibrin thrombi.

- Most common signs/symptoms :
- Slow-growing, freely movable, soft mass
- Subcutaneous lipomas more frequently palpable + painless
- Multiple lipomas may occur bilaterally in 3%

Angiolipoma: 5-17% of benign fatty tumours, more common in the upper extremities, abdomen, back

Differential Diagnosis:

- Benign Fat-Containing Lesions
 - • Fibroadenolipoma (hamartoma)
 - • Fat necrosis
 - • Hibernoma
 - • Cosmetic fat grafting or injections
- Liposarcoma and Atypical Lipoma



Lipoma is the most common soft tissue tumour in adults

Chapter Outline

Breast Anatomy

Anatomical Variants

Pregnancy and Lactation

Diagnostic Imaging Techniques

▶ Disease of the Breast: Benign
▶ Lipoma and Angiolipoma

Disease of the Breast: Malignant

Axilla

Interventional Procedures

Screening

High Risk Women

Communication

Multidisciplinary Team Meeting

Take-Home Messages

References

Test Your Knowledge



Lipoma and Angiolipoma – Imaging



Mammographic Findings:

- **Lipoma:** Fat-only (radiolucent), **circumscribed**, oval or round mass
 Mass effect on surrounding tissue (displaces vessels, muscle, nodes)
- **Angiolipoma:** Circumscribed, fat-containing mass; may show soft tissue density due to capillary networks, fibrin thrombi

US Findings:

- **Lipoma:** Circumscribed, oval or round mass
 Slightly **hyperechoic** or **isoechoic** to subcutaneous fat
 Compresses/displaces adjacent muscle, glandular tissue
- **Angiolipoma:** Circumscribed usually hyperechoic mass, may have hypoechoic foci
- **Both:** Little or no internal vascularity on Doppler

Chapter Outline

Breast Anatomy

Anatomical Variants

Pregnancy and Lactation

Diagnostic Imaging Techniques

▶ **Disease of the Breast: Benign**
 ▶ Lipoma and Angiolipoma

Disease of the Breast: Malignant

Axilla

Interventional Procedures

Screening

High Risk Women

Communication

Multidisciplinary Team Meeting

Take-Home Messages

References

Test Your Knowledge

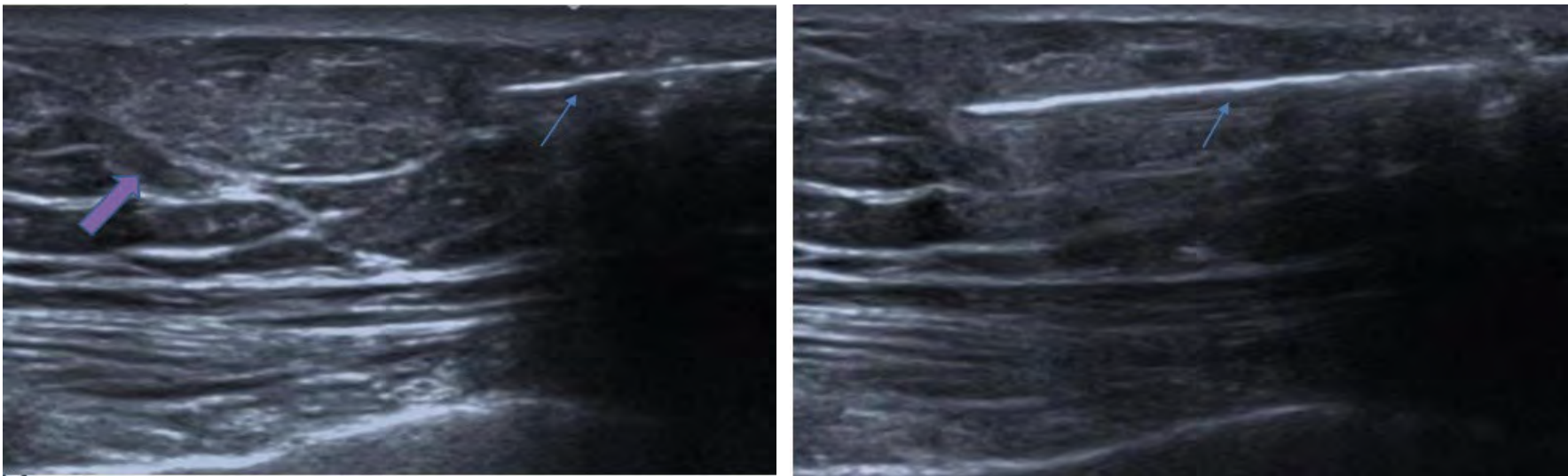


Lipoma and Angiolipoma – Imaging



MRI Findings

- Lipoma: Circumscribed, T1-hyperintense, nonenhancing fatty mass
- Angiolipoma: Fatty mass, may contain hypointense foci on T1 & T2



(Left) 39-year-old woman had a longstanding palpable lump in her right breast. US shows an elongated, oval, circumscribed mass (purple arrow) without internal vascularity, which was isoechoic or very slightly hyperechoic to the subcutaneous fat, consistent with benign lipoma.
(Right) US-guided biopsy concordant.

Chapter Outline

Breast Anatomy

Anatomical Variants

Pregnancy and Lactation

Diagnostic Imaging Techniques

▶ Disease of the Breast: Benign
▶ Lipoma and Angiolipoma

Disease of the Breast: Malignant

Axilla

Interventional Procedures

Screening

High Risk Women

Communication

Multidisciplinary Team Meeting

Take-Home Messages

References

Test Your Knowledge



Mastitis



Mastitis = focal or diffuse breast inflammation, usually infectious. There are several distinct clinical entities:

- **Puerperal mastitis:** in lactating breast; bacterial; **responds well** to conservative treatment & oral antibiotics
- **Non-puerperal mastitis:** broad category of non-lactational bacterial infection; includes iatrogenic; often **chronic, recurrent**, refractory to conservative therapy
- Most common **causative organisms**
 - Staphylococcus (aureus or epidermidis); methicillinresistant S. aureus (MRSA): more localized & invasive
 - Streptococcus: More diffuse; associated with cellulitis
- Most common **signs/symptoms**
 - Diffuse or focal pain/tenderness, erythema, edema, warmth
 - Palpable, tender lump (abscess, inflammatory mass)
 - ± nipple retraction, discharge, fever, leukocytosis

Treatment



- Oral systemic antibiotics & warm compresses, analgesics
- If symptoms do not resolve promptly, US should be performed to **exclude abscess**
 - If (+) abscess: US-guided aspiration=> culture & sensitivity, pathogen-specific antibiotics
- Repeat aspiration may be necessary



Chapter Outline

Breast Anatomy

Anatomical Variants

Pregnancy and Lactation

Diagnostic Imaging Techniques

▶ **Disease of the Breast: Benign**
▶ Mastitis/Abscess

Disease of the Breast: Malignant

Axilla

Interventional Procedures

Screening

High Risk Women

Communication

Multidisciplinary Team Meeting

Take-Home Messages

References

Test Your Knowledge



Mastitis/Abscess – Imaging



Mammography Findings:

- Not routinely performed in puerperal mastitis (clinical diagnosis)
- Diffuse or focal: **↑ breast density, skin & trabecular thickening**
- ± dilated subareolar ducts, may extend peripherally
- Irregular mass: **Consider abscess** or nonbacterial mastitis
- **Adenopathy** often present

MRI Findings:

- STIR: **↑ T2 signal** in areas of edema
 - **Focal T2-hyperintense collection(s)** suggest abscess
- T1WI C+ FS: Focal non-mass enhancement can be seen
 - **Rim-enhancing** mass suggests abscess or malignancy

US Findings:

- Diffuse or focal skin thickening, **↑ echogenicity** due to edema, ± hyperemia on Doppler
- ± dilated lymphatics, intraductal debris, thickened duct walls
- Possible fluid collection ± mobile echoes, fluid-debris level, thick wall:
Abscess
- Often reactive axillary nodes with diffusely thickened cortices



Chapter Outline

Breast Anatomy

Anatomical Variants

Pregnancy and Lactation

Diagnostic Imaging Techniques

▶ **Disease of the Breast: Benign**
▶ Mastitis/Abscess

Disease of the Breast: Malignant

Axilla

Interventional Procedures

Screening

High Risk Women

Communication

Multidisciplinary Team Meeting

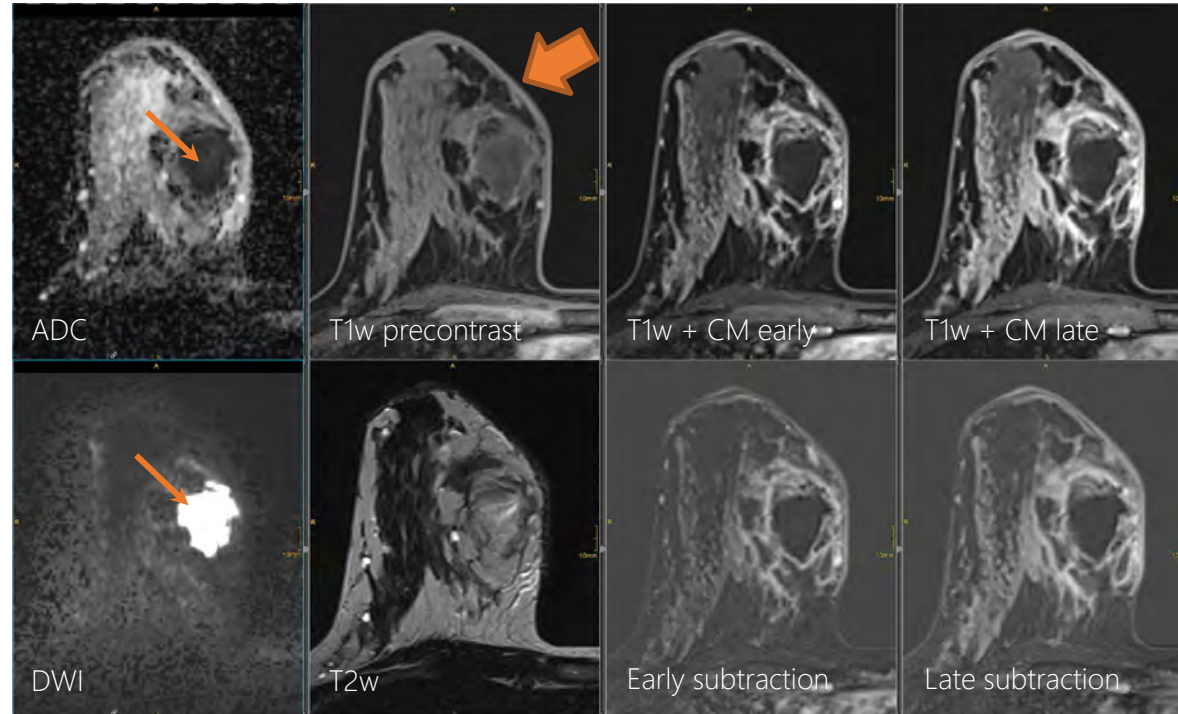
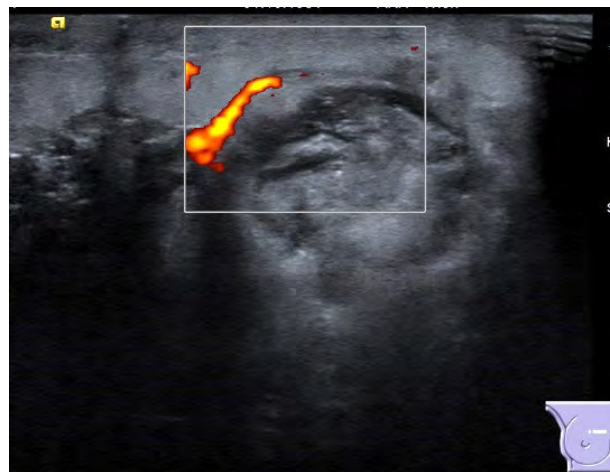
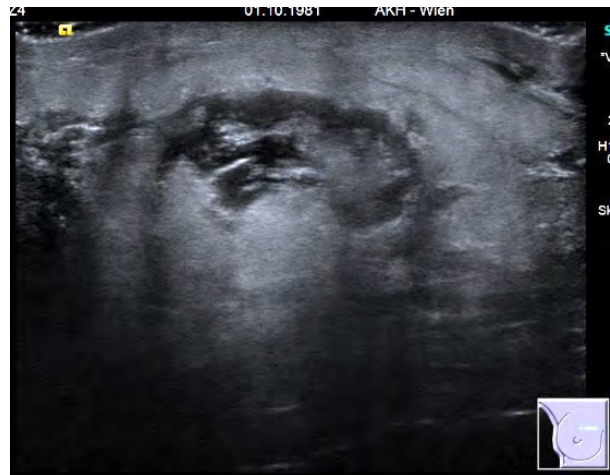
Take-Home Messages

References

Test Your Knowledge



Mastitis/Abscess – Imaging



A 29-year-old woman with 2-week history of right mastitis, presents with a medial, tender lump with associated warmth and erythema. **(Upper)** Targeted US shows skin thickening, a hypoechoic collection surrounded by increased echogenicity due to edema. Vessels in rim on color Doppler imaging.

(Lower) (same patient) T2w MRI shows intermediate-intensity fluid collection and skin edema (thick arrow). Diffusion hindered abscess cavity has very high DWI signal and low ADC (thin arrow). T1w+ CM shows rim enhancing mass and skin enhancement

Chapter Outline

- Breast Anatomy
- Anatomical Variants
- Pregnancy and Lactation
- Diagnostic Imaging Techniques
- ▶ Disease of the Breast: Benign
 - ▶ Mastitis/Abscess
- Disease of the Breast: Malignant
- Axilla
- Interventional Procedures
- Screening
- High Risk Women
- Communication
- Multidisciplinary Team Meeting
- Take-Home Messages
- References
- Test Your Knowledge



Hematoma



Hematoma is the localized collection of extravasated blood.

Etiology: Trauma, iatrogenic (biopsy, surgery), spontaneous (bleeding diathesis, anticoagulant therapy)

Signs and symptoms:

- Painful, palpable, tender lump after known trauma or intervention; may occur spontaneously
- Overlying ecchymosis, skin discoloration
- Initially firm on palpation, may be fluctuant as hematoma evolves

Most resolve rapidly and spontaneously without intervention

- Post-traumatic typically ≤ 6 weeks, postlumpectomy often ≥ 1 year
- May evolve into fat necrosis with oil cyst formation



Chapter Outline

Breast Anatomy

Anatomical Variants

Pregnancy and Lactation

Diagnostic Imaging Techniques

▶ **Disease of the Breast: Benign**
▶ Hematoma

Disease of the Breast: Malignant

Axilla

Interventional Procedures

Screening

High Risk Women

Communication

Multidisciplinary Team Meeting

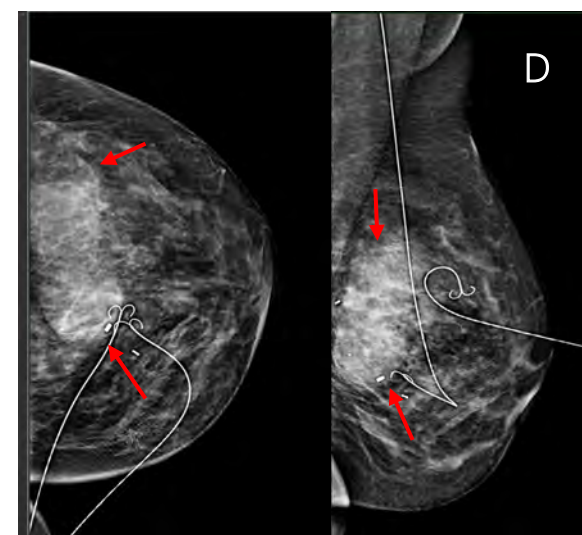
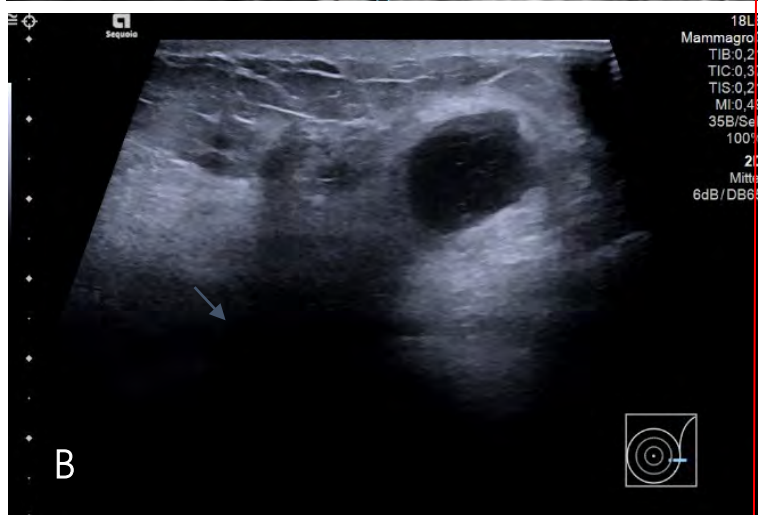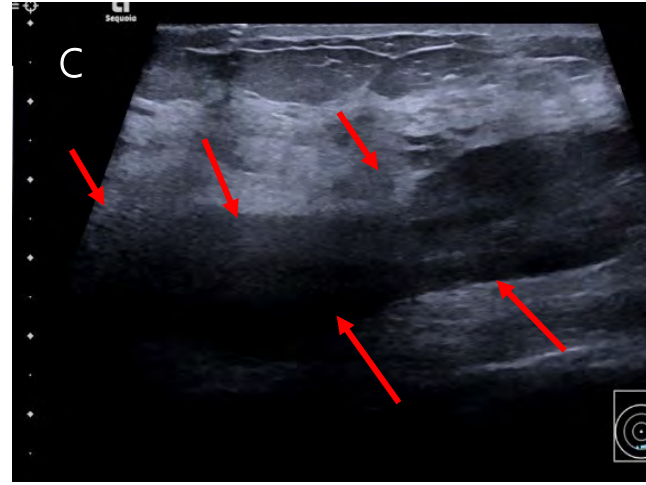
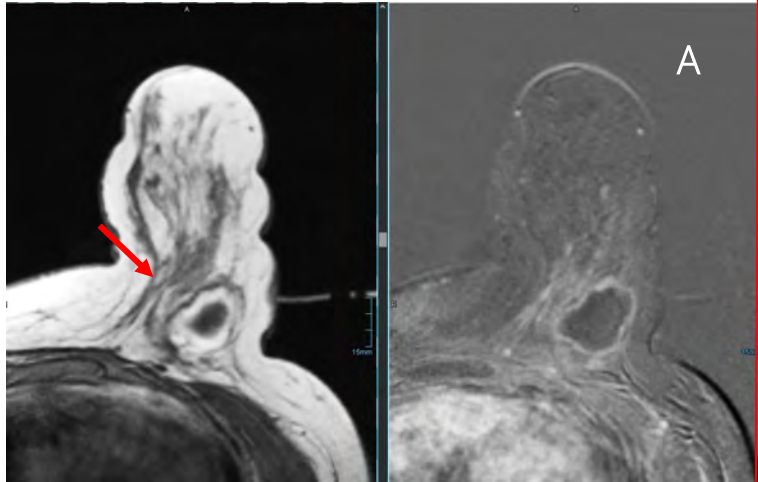
Take-Home Messages

References

Test Your Knowledge



Hematoma – Imaging



A 44-year-old woman with left breast suspicious lesion (not shown) presented for MR-guided biopsy. MR shows a 2-cm mass with low signal on T1, and with very thin peripheral enhancement on T1 C+ FS (A), consistent with acute hematoma during biopsy. Targeted US from same-day right after biopsy shows mildly irregular hypoechoic mass (B). Control US (C) performed 2 weeks later displays a 10-cm acute hematoma with internal echoes (arrows). Control MG (D), on the day of wire-marking shows a circumscribed mass lesion developed compatible with a hematoma.

Chapter Outline

- Breast Anatomy
- Anatomical Variants
- Pregnancy and Lactation
- Diagnostic Imaging Techniques
- ▶ Disease of the Breast: Benign
 - ▶ Hematoma
- Disease of the Breast: Malignant
- Axilla
- Interventional Procedures
- Screening
- High Risk Women
- Communication
- Multidisciplinary Team Meeting
- Take-Home Messages
- References
- Test Your Knowledge



Fat Necrosis



Fat necrosis within the breast is a pathological process that occurs when there is saponification of local fat. It is a benign inflammatory process and is becoming increasingly common with the greater use of breast-conserving surgery and mammoplasty procedures.

Etiology

- No history of prior trauma or surgery in 35-50%
- Accidental injury (blunt or penetrating trauma)
- Surgery/procedures (e.g. reduction mammoplasty)
- Spontaneous development in patients with diabetes
- Chemical irritation (ruptured cyst or ectatic ducts)



Presentation:

-> Highly variable
May be asymptomatic on screening
Tender or nontender, palpable mass or masses
Firm, fixed mass, retraction

Chapter Outline

Breast Anatomy

Anatomical Variants

Pregnancy and Lactation

Diagnostic Imaging Techniques

▶ Disease of the Breast: Benign
▶ Fat Necrosis

Disease of the Breast: Malignant

Axilla

Interventional Procedures

Screening

High Risk Women

Communication

Multidisciplinary Team Meeting

Take-Home Messages

References

Test Your Knowledge



Fat Necrosis – Imaging



Mammography findings:

- Round, oval, or lobulated lucent mass
 - Surrounding increased density due to edema, fibrosis, inflammatory infiltrate
 - Develop peripheral rim calcifications over time
- Calcifications
 - Curvilinear, eggshell, at edge of oil cyst(s) or lobulated fatty mass
 - Calc. due to fat necrosis can develop many years after trauma/surgery
 - Coarse heterogeneous or curvilinear calc. **most common**; become coarser, dystrophic
 - Fine linear or pleomorphic Ca^{++} less common
- Spiculated or irregular mass/asymmetry
 - Due to fibrosis/desmoplastic reaction
- Trabecular thickening due to edema should decrease over 3-6 months

Calcifications
rarely seen < 1.5
years after
trauma/surgery!!

Chapter Outline

Breast Anatomy

Anatomical Variants

Pregnancy and Lactation

Diagnostic Imaging Techniques

▶ Disease of the Breast: Benign
▶ Fat Necrosis

Disease of the Breast: Malignant

Axilla

Interventional Procedures

Screening

High Risk Women

Communication

Multidisciplinary Team Meeting

Take-Home Messages

References

Test Your Knowledge



Fat Necrosis – Imaging



US Findings:

- Sonographic appearances **evolve** over time
 - **Acute phase:** Within days of event– Edema of breast fat → increased echogenicity
 - **Subacute:** ill-defined complex cystic areas within edematous fat
 - **Late phase: (≥ 18 months)** Wall calcifies: Intense posterior shadowing, spiculated mass with echogenic rim, distortion
- Characteristically **within fat lobule** rather than between fat lobules
- **Color or power Doppler:** Internal flow may suggest **recurrent tumour** in lumpectomy patient

Location : Most common in areas subareolar and superficial areas near skin

Chapter Outline

Breast Anatomy

Anatomical Variants

Pregnancy and Lactation

Diagnostic Imaging Techniques

▶ **Disease of the Breast: Benign**
▶ Fat Necrosis

Disease of the Breast: Malignant

Axilla

Interventional Procedures

Screening

High Risk Women

Communication

Multidisciplinary Team Meeting

Take-Home Messages

References

Test Your Knowledge



Fat Necrosis – Imaging



MR Findings:

- T1WI: High-signal central fat; suppresses more than normal fat on T1 FS
- STIR: Low signal ("black hole") with fat suppression, darker than normal fat
- DWI: Unrestricted diffusion
- T1WI C+ FS
 - ~ 25% show no enhancement
 - ~ 75% thin rim of peripheral enhancement – May persist up to 5 years post trauma/surgery

Differential diagnosis:

- Encapsulated Fat-Containing Lesions : Lipoma, Fibroadenolipoma, Galactocele
- Ductal Carcinoma In Situ
 - Fine linear, pleomorphic Ca⁺⁺, can be similar to fat necrosis
- Invasive Ductal or Lobular Carcinoma
 - No history of trauma; irregular mass ± Ca⁺⁺

Chapter Outline

Breast Anatomy

Anatomical Variants

Pregnancy and Lactation

Diagnostic Imaging Techniques

▶ Disease of the Breast: Benign
▶ Fat Necrosis

Disease of the Breast: Malignant

Axilla

Interventional Procedures

Screening

High Risk Women

Communication

Multidisciplinary Team Meeting

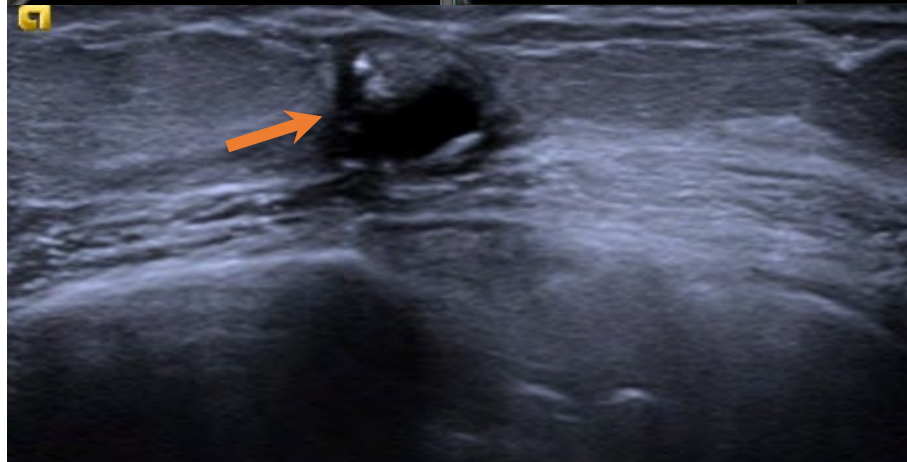
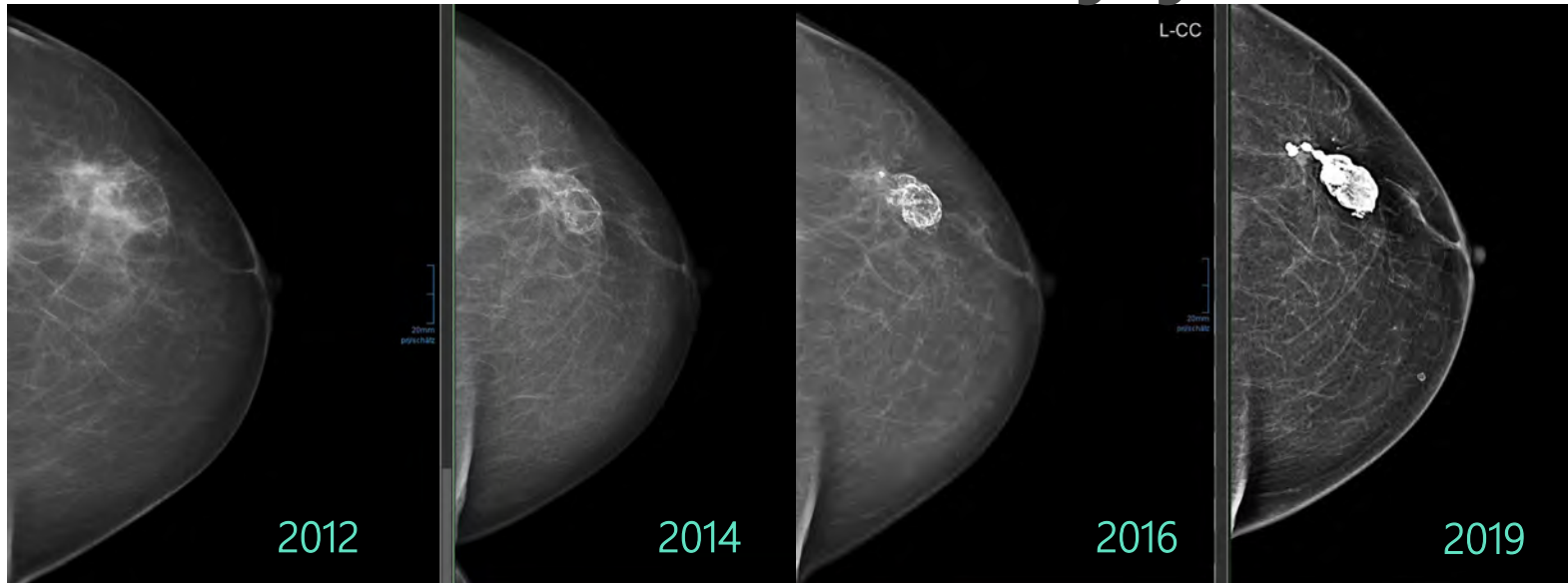
Take-Home Messages

References

Test Your Knowledge



Fat Necrosis – Imaging



A 52-year-old woman in follow-up after left lumpectomy for DCIS. On CC (upper) mammograms, calcifying fat necrosis is seen at the lumpectomy scar over the years. Targeted US shows a centrally anechoic partially circumscribed mass with calcifications (arrow). The mass is within the subcutaneous fat.

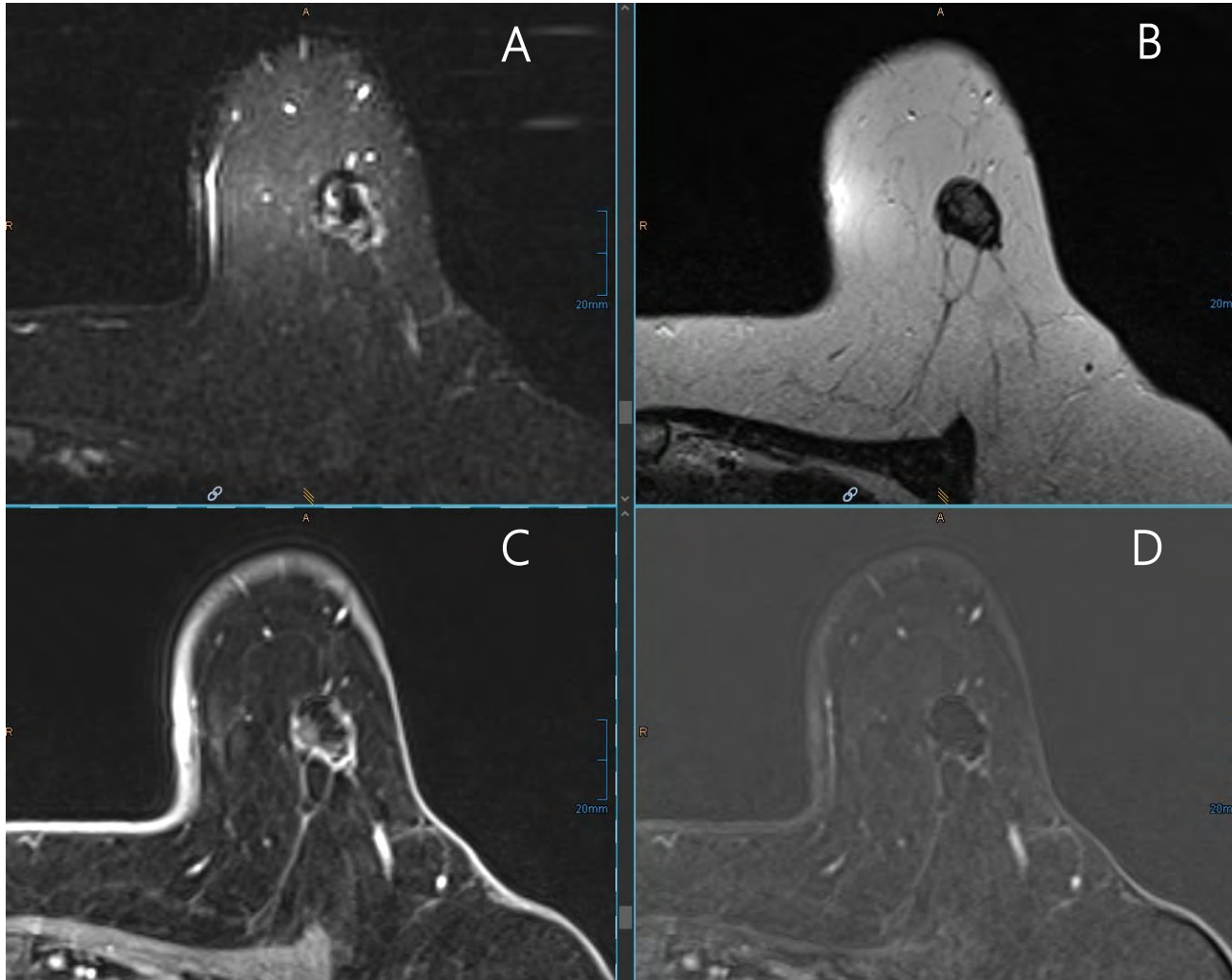
→
to be continued

Chapter Outline

- Breast Anatomy
- Anatomical Variants
- Pregnancy and Lactation
- Diagnostic Imaging Techniques
- ▶ Disease of the Breast: Benign
 - ▶ Fat Necrosis
- Disease of the Breast: Malignant
- Axilla
- Interventional Procedures
- Screening
- High Risk Women
- Communication
- Multidisciplinary Team Meeting
- Take-Home Messages
- References
- Test Your Knowledge



Fat Necrosis – Imaging



Axial STIR MR (A) (same patient) shows a peripherally T2-hyperintense, oval mass with central signal void due to fat necrosis having a shorter T1 time as normal fat (which is grey). Axial T2w without fat sat (B) shows a centrally mildly hyperintense mass with internal hypointense areas (likely calcifications). Axial T1 C+ FS and subtraction (C-D) MR shows minimal non-solid rim enhancement in this mass that is centrally hypointense and lacks central enhancement. Findings are consistent with fat necrosis.

Chapter Outline

- Breast Anatomy
- Anatomical Variants
- Pregnancy and Lactation
- Diagnostic Imaging Techniques
- ▶ Disease of the Breast: Benign
 - ▶ Fat Necrosis
- Disease of the Breast: Malignant
- Axilla
- Interventional Procedures
- Screening
- High Risk Women
- Communication
- Multidisciplinary Team Meeting
- Take-Home Messages
- References
- Test Your Knowledge



Indications, Advantages and Disadvantages of Diagnostic Techniques in Malignant Breast Lesions



- **Mammography** (diagnostic imaging, bilateral 2 views and additional views)
 - High specificity
 - Low sensitivity in dense breasts
 - High sensitivity for microcalcifications related in situ breast cancer
 - Stereotactic guided biopsy for mammographically detected lesions (most frequent microcalcifications)
- **Ultrasound (US)** of bilateral breast and axilla
 - Differentiation between mass and cystic lesion
 - Low specificity
 - Biopsy guided technique for the exploration of breast lesions
- **Magnetic resonance imaging (MRI)**
 - High sensitivity and specificity
 - Biopsy guided technique for the exploration of MRI detected lesions

Mammography and US are mandatory in the investigation of all suspicious breast lesions. Additional MRI is strongly advised in case of an invasive lobular carcinoma, a dense breast, a positive family history, a gene mutation carrier and suspiciousness of multicentric or bilateral breast cancer.



Chapter Outline

Breast Anatomy

Anatomical Variants

Pregnancy and Lactation

Diagnostic Imaging Techniques

Disease of the Breast: Benign

▶ **Disease of the Breast: Malignant**
▶ Imaging and Diagnostic Techniques

Axilla

Interventional Procedures

Screening

High Risk Women

Communication

Multidisciplinary Team Meeting

Take-Home Messages

References

Test Your Knowledge



A **triple assessment** is mandatory for the investigation of suspicious breast lesions. It consists of a clinical examination by a trained professional, a radiological investigation and a biopsy procedure.



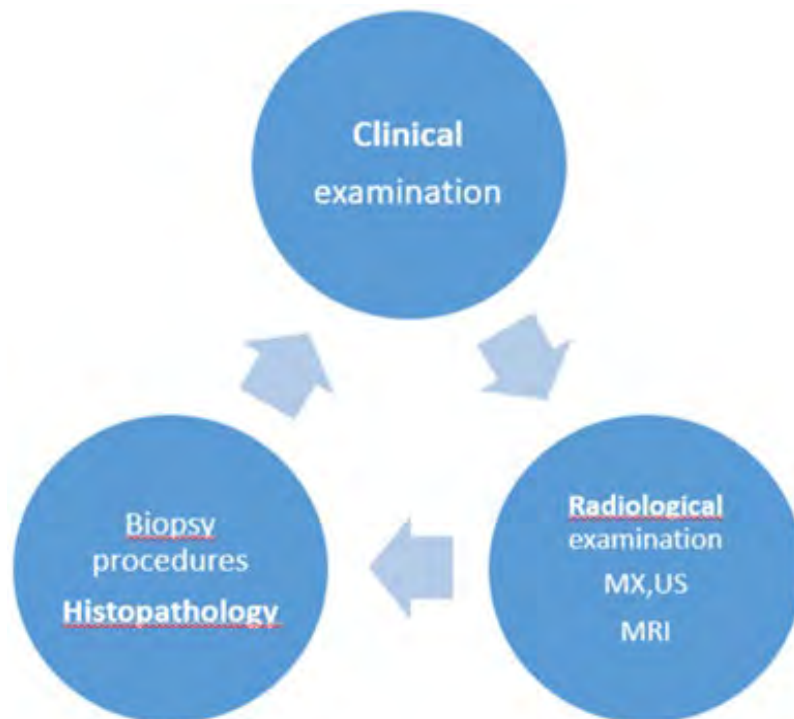Final correlation between pathology results, clinical and imaging findings is mandatory. If a discrepancy occur, additional imaging is necessary!

A mammography (MX), ultrasound and MRI report contains a full description of both breasts, a final assessment, impression and recommendation.

A uniform description and assessment helps the radiologist to communicate about the imaging results. One of the most frequently used protocol is the Breast Imaging Reporting and Database System (BI-RADS).

In this chapter, the BI-RADS descriptors will be used to explain the presentations of malignant lesions in the breast on MX, US and MRI.

www.ACR.org



Chapter Outline

Breast Anatomy

Anatomical Variants

Pregnancy and Lactation

Diagnostic Imaging Techniques

Disease of the Breast: Benign

▶ Disease of the Breast: Malignant
▶ Imaging and Diagnostic Techniques

Axilla

Interventional Procedures

Screening

High Risk Women

Communication

Multidisciplinary Team Meeting

Take-Home Messages

References

Test Your Knowledge



A breast imaging report contains

- Clinical information and indication
- Comparison with priors (date and type of exam)
- Breast density - Tissue composition- enhancement pattern
- Skin, nipple and areola
- Lesions
 - Mass, Asymmetry, Stellate lesion
 - Calcifications
- Location, size of each lesion, distance to the nipple
- Secondary signs (skin, nipple)
- Lymph node status
- Assessment category
- Recommendations

www.ACR.org

Chapter Outline

Breast Anatomy

Anatomical Variants

Pregnancy and Lactation

Diagnostic Imaging Techniques

Disease of the Breast: Benign

- ▶ Disease of the Breast: Malignant
 - ▶ Imaging and Diagnostic Techniques

Axilla

Interventional Procedures

Screening

High Risk Women

Communication

Multidisciplinary Team Meeting

Take-Home Messages


References

Test Your Knowledge



On mammography malignant lesions can present as a

- Mass
- Architectural distortion
- Asymmetry
- Microcalcifications



Chapter Outline

- Breast Anatomy
- Anatomical Variants
- Pregnancy and Lactation
- Diagnostic Imaging Techniques
- Disease of the Breast: Benign
- ▶ Disease of the Breast: Malignant
 - ▶ Imaging and Diagnostic Techniques
- Axilla
- Interventional Procedures
- Screening
- High Risk Women
- Communication
- Multidisciplinary Team Meeting
- Take-Home Messages
- References
- Test Your Knowledge

ACR BI-RADS® Atlas Fifth Edition QUICK REFERENCE		MAMMOGRAPHY		
Breast composition	a. The breasts are almost entirely fatty b. There are scattered areas of fibroglandular density c. The breasts are heterogeneously dense, which may obscure small masses d. The breasts are extremely dense, which lowers the sensitivity of mammography			
Masses	Shape	Oval Round Irregular		
	Margin	Circumscribed Obscured Microlobulated Indistinct Spiculated		
	Density	High density Equal density Low density Fat-containing		
Calcifications	Typically benign	Skin Vascular Coarse or "popcorn-like" Large rod-like Round Rim Dystrophic Milk of calcium Suture	Asymmetries	Asymmetry Global asymmetry Focal asymmetry Developing asymmetry
	Suspicious morphology	Amorphous Coarse heterogeneous Fine pleomorphic Fine linear or fine-linear branching	Intramammary lymph node	
	Distribution	Diffuse Regional Grouped Linear Segmental	Skin lesion	
	Architectural distortion		Solitary dilated duct	
	Asymmetries	Asymmetry Global asymmetry Focal asymmetry Developing asymmetry	Associated features	Skin retraction Nipple retraction Skin thickening Trabecular thickening Axillary adenopathy Architectural distortion Calcifications
			Location of lesion	Laterality Quadrant and clock face Depth Distance from the nipple



On **mammography** a malignant mass has an irregular shape with microlobulated, indistinct or spiculated margins. The density is higher than the surrounding tissue. Associated signs of malignancy are suspicious microcalcifications. Associated findings can be skin and nipple retraction and thickening.



Mammography

Mass =>

Shape: oval (may include 2 or 3 lobulations), round, **irregular**

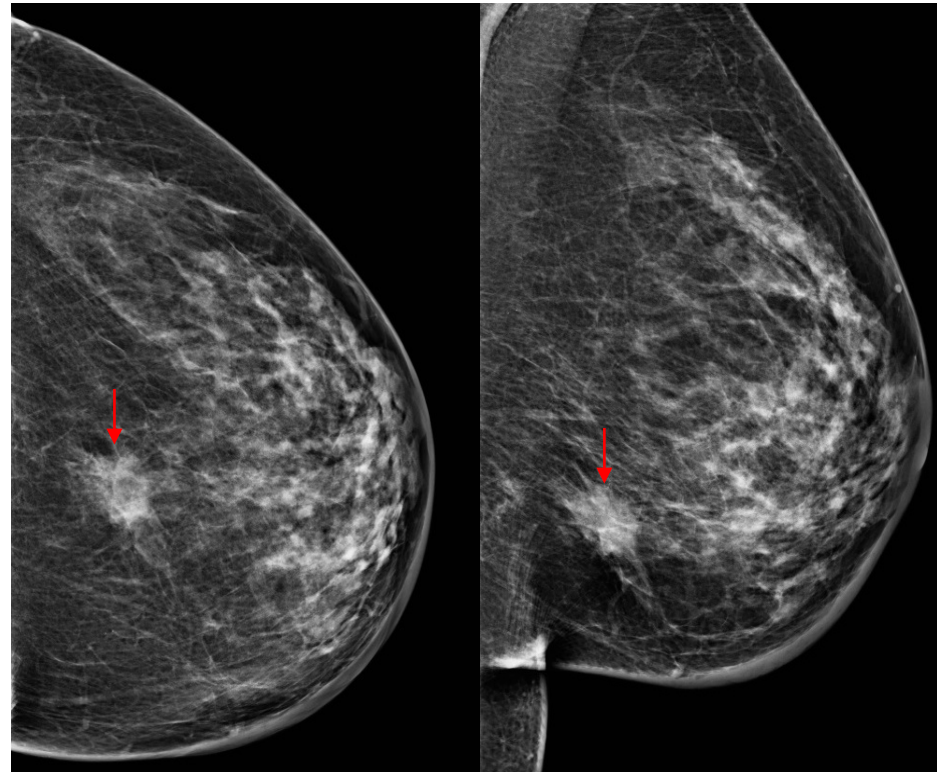
Margins: circumscribed, **obscured, microlobulated, indistinct, spiculated**

Density: **high**, equal, low or fat-containing.

Associated microcalcifications

Associated findings: skin thickening,

Location (left/right, quadrant, clock-wise, periareolar, middle, posterior)



Mass lesion (arrow) with an irregular shape, spiculated margins and high density. Skin thickening of the inner and lower part of the breast. Pathology showed an invasive ductal carcinoma 25 mm in size.

Chapter Outline

Breast Anatomy

Anatomical Variants

Pregnancy and Lactation

Diagnostic Imaging Techniques

Disease of the Breast: Benign

▶ Disease of the Breast: Malignant
▶ Imaging and Diagnostic Techniques

Axilla

Interventional Procedures

Screening

High Risk Women

Communication

Multidisciplinary Team Meeting

Take-Home Messages

References

Test Your Knowledge

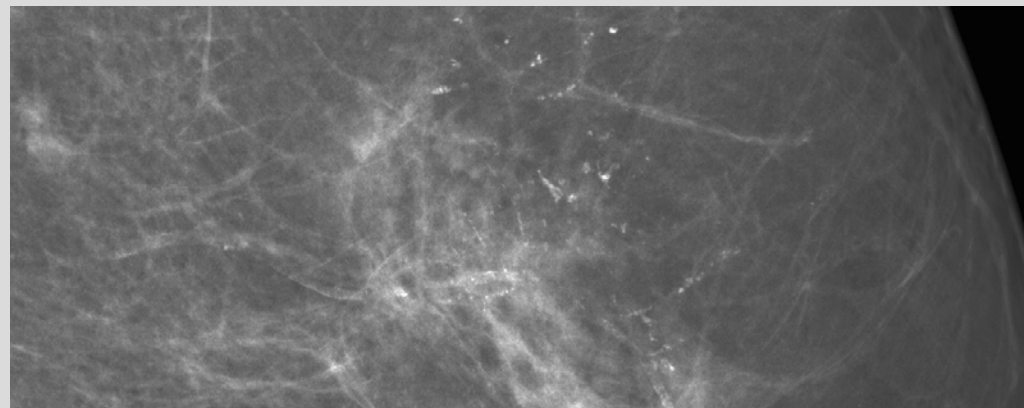


- **Microcalcifications** can be associated with a malignant mass but can also be present as the only finding in ductal carcinoma in situ.
- The amount, type and distribution of microcalcifications should be analysed: fine linear or branching microcalcifications in a linear and segmental distributions are very suspicious for ductal carcinoma in situ (DCIS).

Mammography

Microcalcifications =>

- **Morphology:** fine-linear branching
- **Distribution:** linear and segmental
- **Change over time:** stability over time of suspicious calcifications is unreliable



Chapter Outline

Breast Anatomy

Anatomical Variants

Pregnancy and Lactation

Diagnostic Imaging Techniques

Disease of the Breast: Benign

- ▶ **Disease of the Breast: Malignant**
 - ▶ Imaging and Diagnostic Techniques

Axilla

Interventional Procedures

Screening

High Risk Women

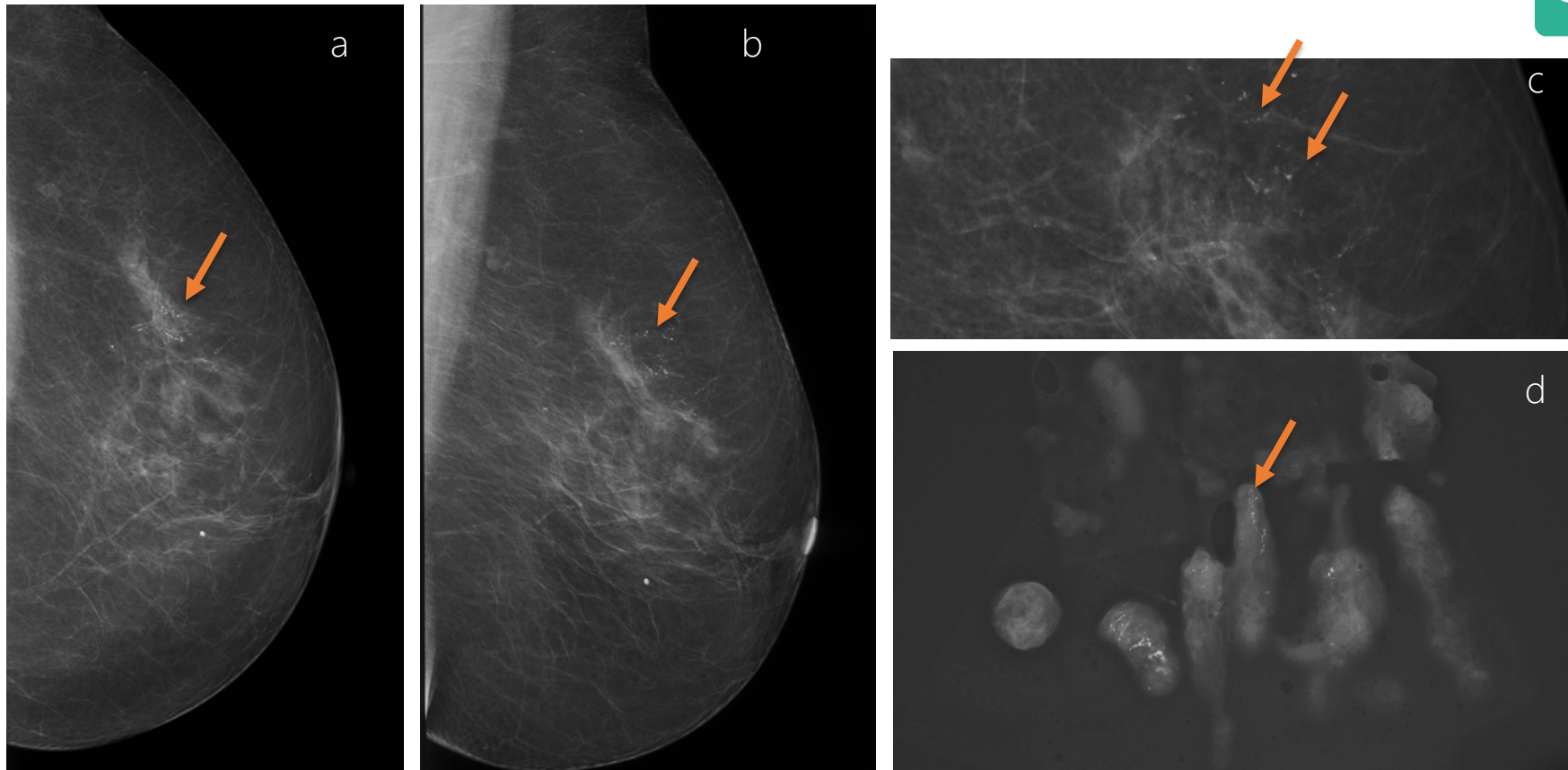
Communication

Multidisciplinary Team Meeting

Take-Home Messages

References

Test Your Knowledge



a and b CC and MLO view of the left breast show a segmental distribution of microcalcifications in the upper outer quadrant, pathology: ductal carcinoma in situ (DCIS)

c Magnification view in MLO shows fine linear branching calcifications, organised in a ductal pattern, in a segmental distribution

d specimen (magnification) image shows the irregular branching or casting calcifications

Chapter Outline

Breast Anatomy

Anatomical Variants

Pregnancy and Lactation

Diagnostic Imaging Techniques

Disease of the Breast: Benign

▶ Disease of the Breast: Malignant
▶ Imaging and Diagnostic Techniques

Axilla

Interventional Procedures

Screening

High Risk Women

Communication

Multidisciplinary Team Meeting

Take-Home Messages

References

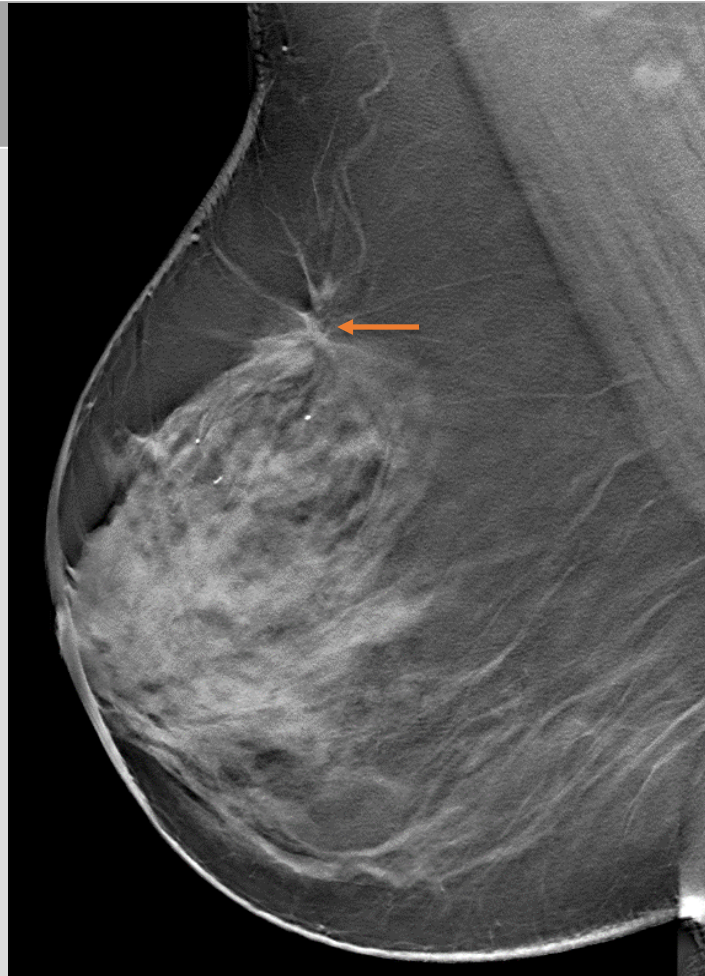
Test Your Knowledge



Mammography

Architectural distortion =>

Thin straight lines or spiculations radiating from a central area, and focal retraction, distortion or straightening at the edges of the parenchyma



Chapter Outline

Breast Anatomy

Anatomical Variants

Pregnancy and Lactation

Diagnostic Imaging Techniques

Disease of the Breast: Benign

▶ Disease of the Breast: Malignant
▶ Imaging and Diagnostic Techniques

Axilla

Interventional Procedures

Screening

High Risk Women

Communication

Multidisciplinary Team Meeting

Take-Home Messages

References

Test Your Knowledge

MLO tomo view of the right breast shows a small distortion in the upper part of the right breast (arrow); pathology revealed an invasive ductal carcinoma of 1,8cm.



Mammography

Asymmetry => area of fibroglandular tissue visible on only one mammographic projection (superimposition of normal breast tissue).

Focal asymmetry visible on two projections, hence a real finding rather than superimposition.

Global asymmetry consisting of an asymmetry over at least one quarter of the breast and is usually a normal variant.

Developing asymmetry new, larger and more conspicuous than on a previous examination. A developing asymmetry is suspicious and needs always further investigation with US and in case of discordant results, MRI.

Chapter Outline

Breast Anatomy

Anatomical Variants

Pregnancy and Lactation

Diagnostic Imaging Techniques

Disease of the Breast: Benign

▶ Disease of the Breast: Malignant
▶ Imaging and Diagnostic Techniques

Axilla

Interventional Procedures

Screening

High Risk Women

Communication

Multidisciplinary Team Meeting

Take-Home Messages

References

Test Your Knowledge



On **ultrasound** a malignant lesions is heterogeneous, hypoechoic (darker) with an irregular shape, and angular, microlobulated or spiculated margins.



The orientation is not parallel to the skin and posterior lesion shadowing is often present.

Ultrasound Lexicon	
Breast composition	a. homogeneous - fat b. homogeneous - fibroglandular c. heterogeneous
Mass	shape oval - round - irregular
	margin Circumscribed or Not-circumscribed: indistinct, angular, microlobulated, spiculated
	orientation parallel - not parallel
	echo pattern anechoic - hyperechoic - complex cystic/solid hypoechoic - isoechoic - heterogeneous
	posterior features no features - enhancement - shadowing - combined pattern
Calcifications	in mass - outside mass - intraductal
Associated features	architectural distortion - duct changes - skin thickening - skin retraction - edema - vascularity (absent, internal, rim) - elasticity
Special cases <i>(cases with a unique diagnosis)</i>	simple cyst - clustered microcysts - complicated cyst - mass in or on skin - foreign body (including implants) - intramammary lymph node - AVM - Mondor disease - postsurgical fluid collection - fat necrosis

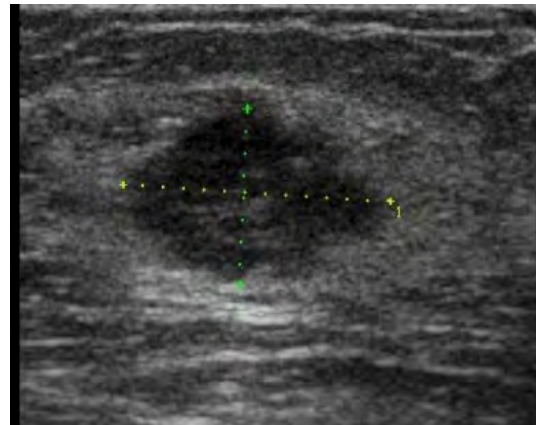


Fig 5: ultrasound image of the mass lesion seen on MX in fig 1 shows an hypoechoic mass with an irregular shape, and microlobulated, angular margins.

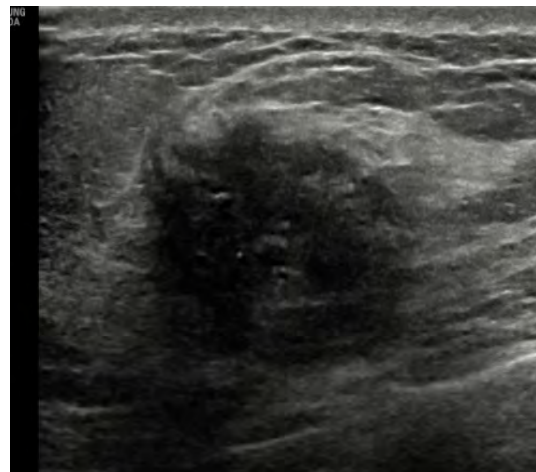


Fig 6: ultrasound image of the mass lesion on MX in fig 2 shows an hypoechoic mass with irregular shape, indistinct margins, with retroacoustic shadow. The reflections in the mass represent the pathological microcalcifications

Chapter Outline

Breast Anatomy

Anatomical Variants

Pregnancy and Lactation

Diagnostic Imaging Techniques

Disease of the Breast: Benign

▶ Disease of the Breast: Malignant
▶ Imaging and Diagnostic Techniques

Axilla

Interventional Procedures

Screening

High Risk Women

Communication

Multidisciplinary Team Meeting

Take-Home Messages

References

Test Your Knowledge



- If the characteristics of the lesion indicate a malignancy, BI-RADS category is 4 (4A, 4B, 4C), 5 or 6 is the final assessment.
- Based on this classification an additional minimal invasive diagnostic technique such as a core needle biopsy must be performed (triple assessment).

BI-RADS® ASSESSMENT CATEGORIES	
Category 0: Mammography: Incomplete – Need Additional Imaging Evaluation and/or Prior Mammograms for Comparison Ultrasound & MRI: Incomplete – Need Additional Imaging Evaluation	
Category 1: Negative	
Category 2: Benign	
Category 3: Probably Benign	
Category 4: Suspicious	Mammography & Ultrasound: Category 4A: Low suspicion for malignancy Category 4B: Moderate suspicion for malignancy Category 4C: High suspicion for malignancy
Category 5: Highly Suggestive of Malignancy	
Category 6: Known Biopsy-Proven Malignancy	

For the complete Atlas, visit acr.org/birads 07.15

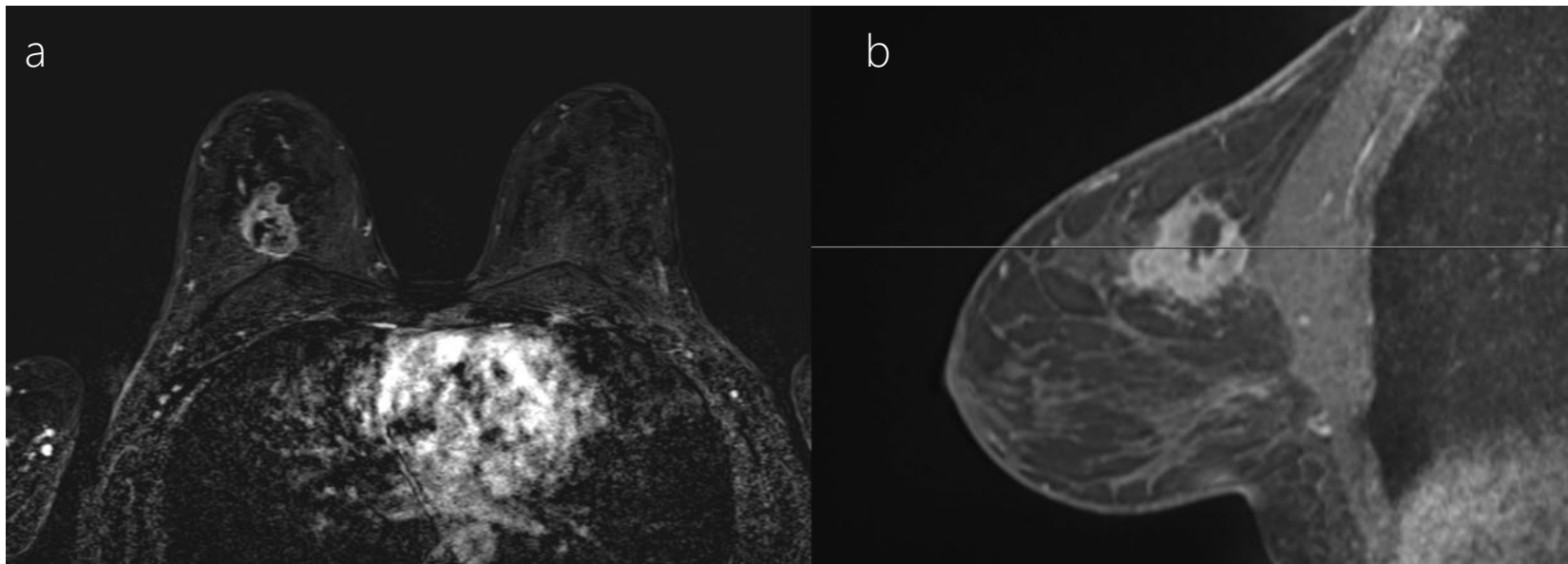
Chapter Outline

- Breast Anatomy
- Anatomical Variants
- Pregnancy and Lactation
- Diagnostic Imaging Techniques
- Disease of the Breast: Benign
- ▶ Disease of the Breast: Malignant
 - ▶ Imaging and Diagnostic Techniques
- Axilla
- Interventional Procedures
- Screening
- High Risk Women
- Communication
- Multidisciplinary Team Meeting
- Take-Home Messages
- References
- Test Your Knowledge





On MRI a malignant lesion shows a heterogeneous and rim enhancement. The shape is irregular and margins are spiculated. Besides the morphology, the lesion shows a rapid increase in signal after the injection of contrast followed by a washout in the delayed phase.



Contrast-enhanced MRI, subtraction image axial plane (a) and T1W with fat suppression sagittal plane (b) of the tumour shows a lesion with heterogeneous and rim enhancement, the shape and margins are irregular. The pattern of enhancement is highly suspicious of malignancy.

Chapter Outline

Breast Anatomy

Anatomical Variants

Pregnancy and Lactation

Diagnostic Imaging Techniques

Disease of the Breast: Benign

▶ Disease of the Breast: Malignant
▶ Imaging and Diagnostic Techniques

Axilla

Interventional Procedures

Screening

High Risk Women

Communication

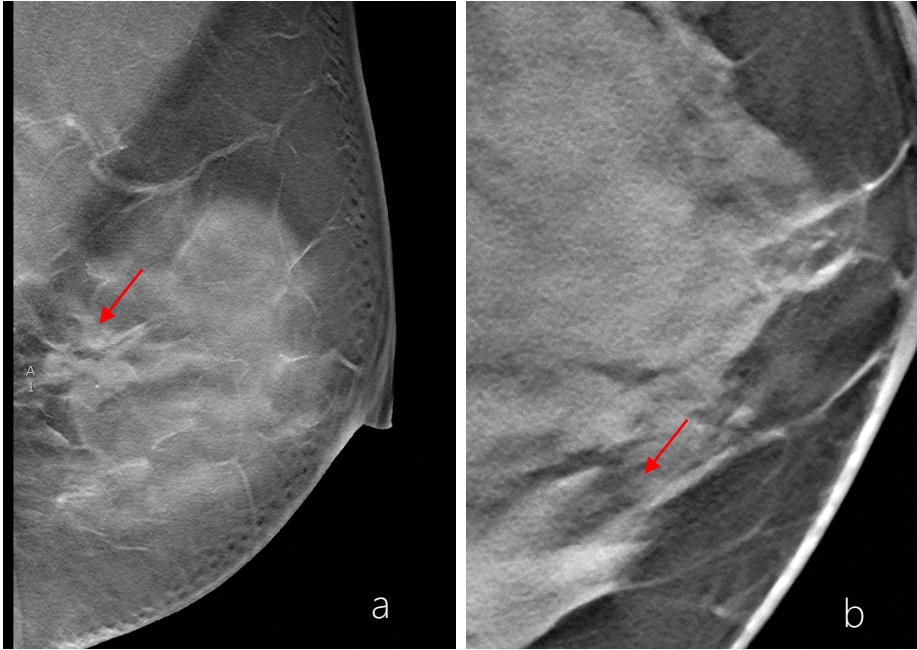
Multidisciplinary Team Meeting

Take-Home Messages

References

Test Your Knowledge



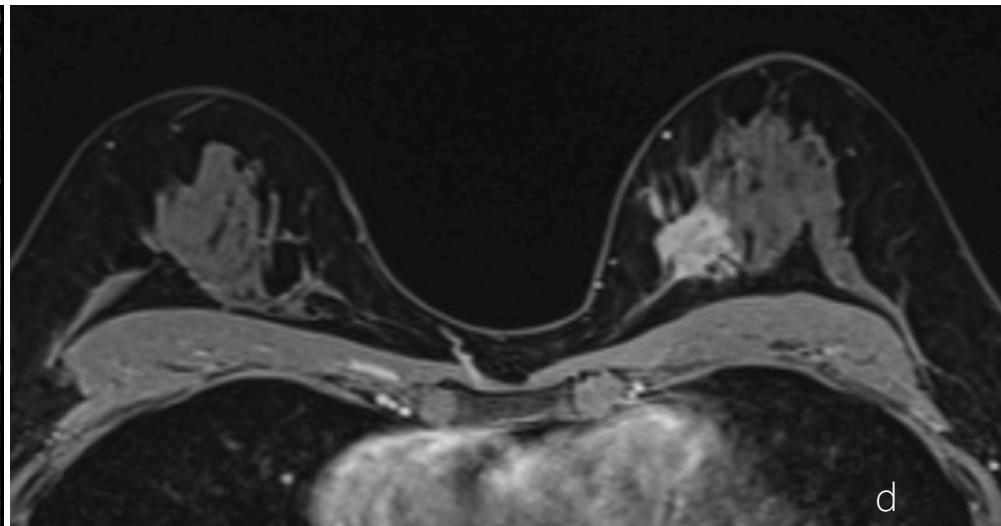
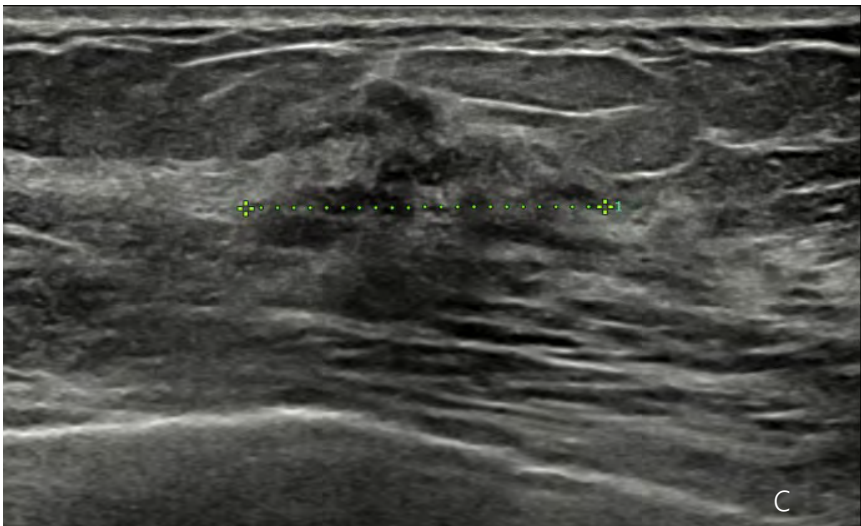


High density mass (a and b) lesion with spiculated margins and irregular shape, medial at 9 o'clock in the left breast on the digital breast tomosynthesis slices (arrow)s.

Ultrasound (c) shows an irregular lesion (between callipers), inhomogeneous, microlobulated.

On MRI (d) a strong enhancing, irregular, spiculated lesion with inhomogeneous enhancement.

Histology revealed an invasive ductal carcinoma of 2,3cm.



Chapter Outline

Breast Anatomy

Anatomical Variants

Pregnancy and Lactation

Diagnostic Imaging Techniques

Disease of the Breast: Benign

▶ Disease of the Breast: Malignant
▶ Imaging and Diagnostic Techniques

Axilla

Interventional Procedures

Screening

High Risk Women

Communication

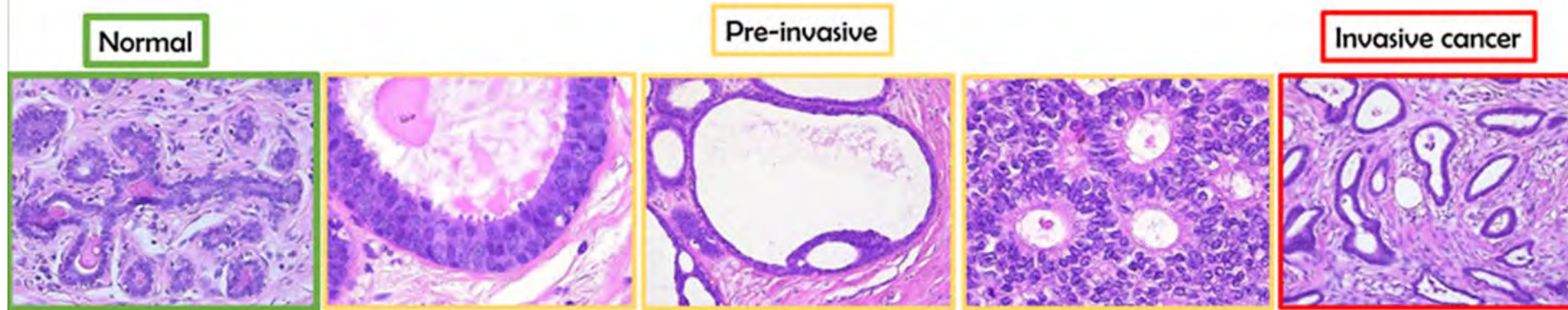
Multidisciplinary Team Meeting

Take-Home Messages

References

Test Your Knowledge

Histology of in Situ & Invasive Breast Cancer



Courtesy: G. Floris, MD, University Hospitals Leuven, Belgium

- Within the normal mammary and **terminal ductal mammary lobar unit (TDLU)**, a layer of epithelial cells and a layer of myoepithelial cells are surrounded by a basement membrane.
- In **DCIS**, the epithelial cells are phenotypically different from normal epithelial cells (poorly differentiated DCIS more than well-differentiated DCIS). However, they are **still surrounded by a basement membrane**.
- DCIS encompasses a group of histologically and prognostically **heterogeneous non-invasive carcinomas**. **Microcalcifications** are the main imaging finding in DCIS.
- Once the neoplastic cells invade the basement membrane into the breast stroma, they have transitioned to an **invasive ductal carcinoma**.

Breast Cancer Biology for the Radiation Oncologist, 2015; ISBN : 978-3-642-31219-9
Chapter: Biology of DCIS and progression to invasive disease.Sanaz A. Jansen
Diagnostic breast imaging, SH Heywant-Köbrinmer, D Dersaw, I Schreer, Thieme



Chapter Outline

Breast Anatomy

Anatomical Variants

Pregnancy and Lactation

Diagnostic Imaging Techniques

Disease of the Breast: Benign

▶ Disease of the Breast: Malignant
▶ Malignant Diseases of the Breast

Axilla

Interventional Procedures

Screening

High Risk Women

Communication

Multidisciplinary Team Meeting

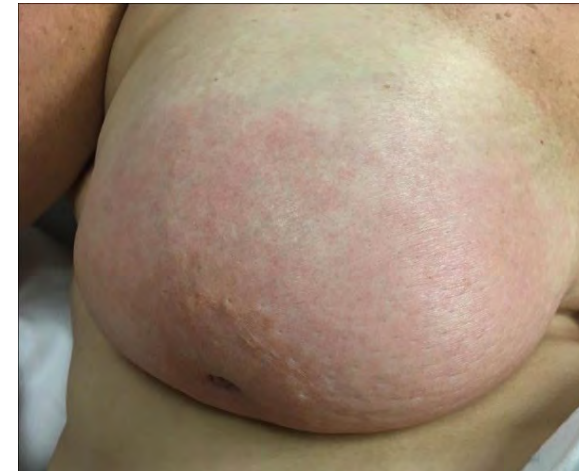Take-Home Messages

References

Test Your Knowledge



- The most frequent type of carcinoma is **invasive ductal carcinoma** (IDC) Not Otherwise Specified (NOS) type (80%), followed by the invasive lobular carcinoma (about 15%) .
- Special types of invasive ductal carcinomas are:
 - Mucinous carcinoma (3%)
 - Tubular carcinoma (2-3%)
 - Medullar carcinoma (3-4%)
 - Papillary carcinoma (2%).
- Mucinous carcinoma and medullary carcinoma are sometimes well circumscribed.
- Therefore, to differentiate from a fibroadenoma, core needle biopsy is indicated in case a new or growing lesion is detected
- Inflammatory breast cancer is a condition in which tumour cells are in the lymphatic skin vessels, responsible for the clinical presentation of oedema, erythema and hyperthermia.
- Other rarer types of carcinoma include Paget's disease of the nipple, malignant phyllodes tumour and sarcoma of the breast



Skin oedema, redness of the right breast, courtesy of Multidisciplinary Breast Center, University Hospitals Leuven, Belgium



Chapter Outline

Breast Anatomy

Anatomical Variants

Pregnancy and Lactation

Diagnostic Imaging Techniques

Disease of the Breast: Benign

▶ Disease of the Breast: Malignant

- ▶ Malignant Diseases of the Breast

Axilla

Interventional Procedures

Screening

High Risk Women

Communication

Multidisciplinary Team Meeting


Take-Home Messages

References

Test Your Knowledge



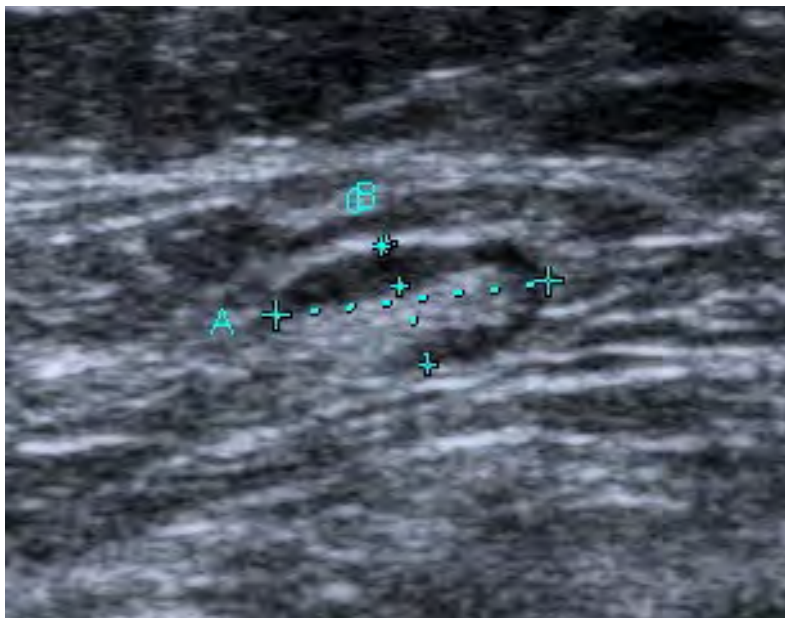
Background



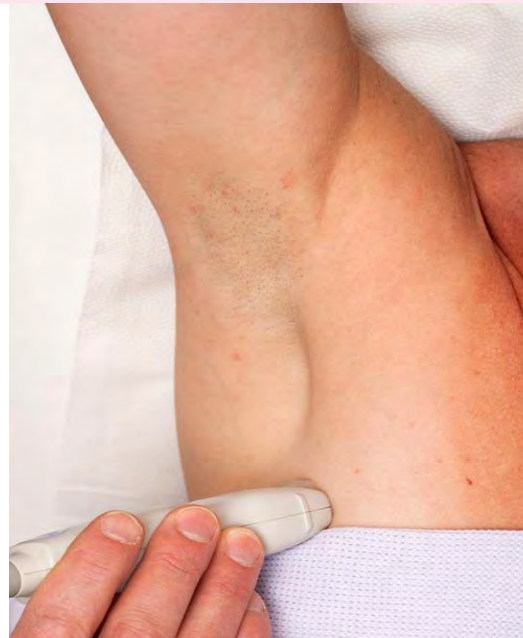The presence of axillary node metastasis remains one of most important prognostic factors in breast cancer .

Approximately 30-40% of newly diagnosed breast cancer patients will have nodal metastases.

It is routine practice to perform axillary ultrasound in all patients with suspected breast cancer on initial imaging.



Ultrasound appearances of an axillary lymph node



Axillary ultrasound being performed in a patient with suspected breast cancer. Note the abducted position of the arm

Chapter Outline

Breast Anatomy

Anatomical Variants

Pregnancy and Lactation

Diagnostic Imaging Techniques

Disease of the Breast: Benign

Disease of the Breast: Malignant

▶ Axilla

▶ Anatomy

Interventional Procedures

Screening

High Risk Women

Communication

Multidisciplinary Team Meeting

Take-Home Messages

References

Test Your Knowledge



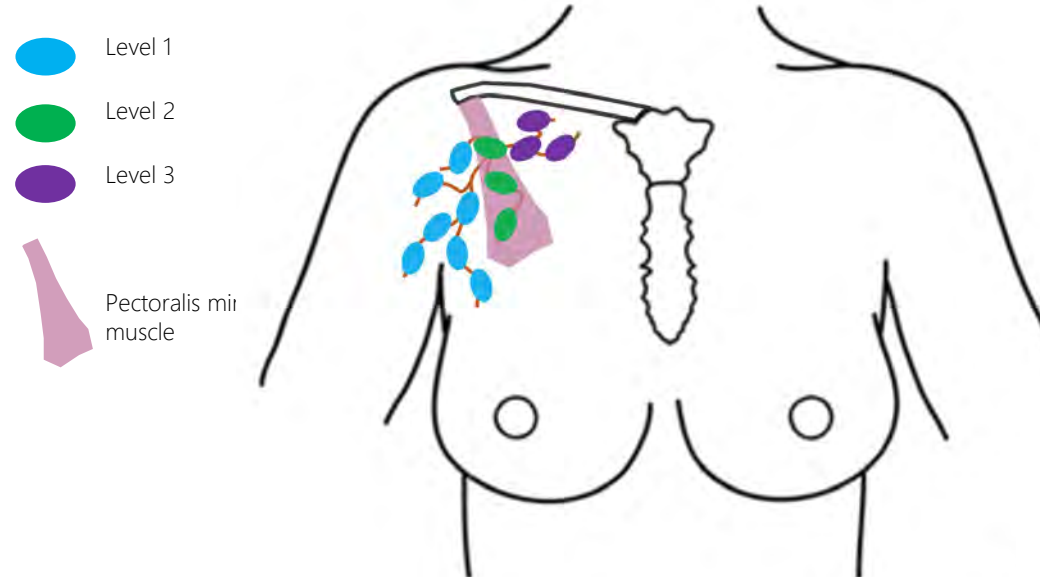
Anatomy of the Axilla



- Anatomically the axilla has a 3 dimensional shape resembling a pyramid, and contains structures including the axillary artery and vein, brachial plexus, and axillary lymph nodes
- The axilla is divided into three levels by the pectoralis minor muscle
- Drainage generally proceeds in a stepwise fashion from level I to II to III, and finally into the thorax



Nodal metastases to level III carry a worse prognosis than metastases to level I and level II axillary nodes



Anatomy of axillary lymph node levels depending on location of the pectoralis minor muscle

Chapter Outline

Breast Anatomy

Anatomical Variants

Pregnancy and Lactation

Diagnostic Imaging Techniques

Disease of the Breast: Benign

Disease of the Breast: Malignant

▶ Axilla
▶ Anatomy

Interventional Procedures

Screening

High Risk Women

Communication

Multidisciplinary Team Meeting


Take-Home Messages

References

Test Your Knowledge



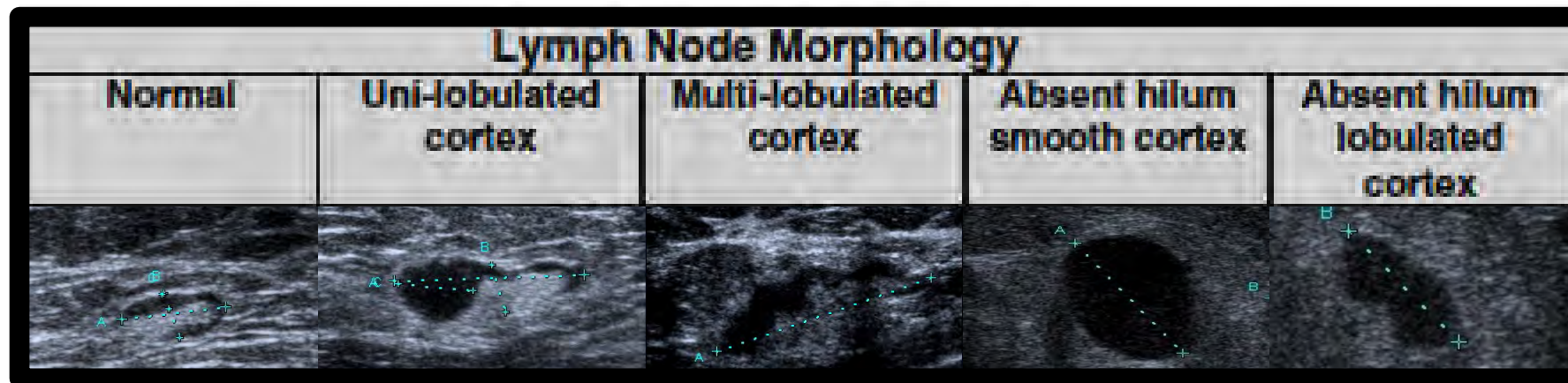
Appearances of Axillary Lymph Nodes on Ultrasound



The normal axillary lymph node should be oval with a smooth, well-defined margin and a uniformly thin hypoechoic cortex. The echogenic hilum should comprise most of the lymph node.

Cortical thickening or a focal cortical budge are considered the earliest detectable changes.

Replacement of the entire node by an ill-defined mass is highly suspicious for malignant involvement of nodes, however this finding is non-specific and is often associated with reactive nodes



Appearances of normal and abnormal axillary lymph nodes on US .

Chapter Outline

Breast Anatomy

Anatomical Variants

Pregnancy and Lactation

Diagnostic Imaging Techniques

Disease of the Breast: Benign

Disease of the Breast: Malignant

▶ Axilla

▶ Appearance on Ultrasound

Interventional Procedures

Screening

High Risk Women

Communication

Multidisciplinary Team Meeting

Take-Home Messages References

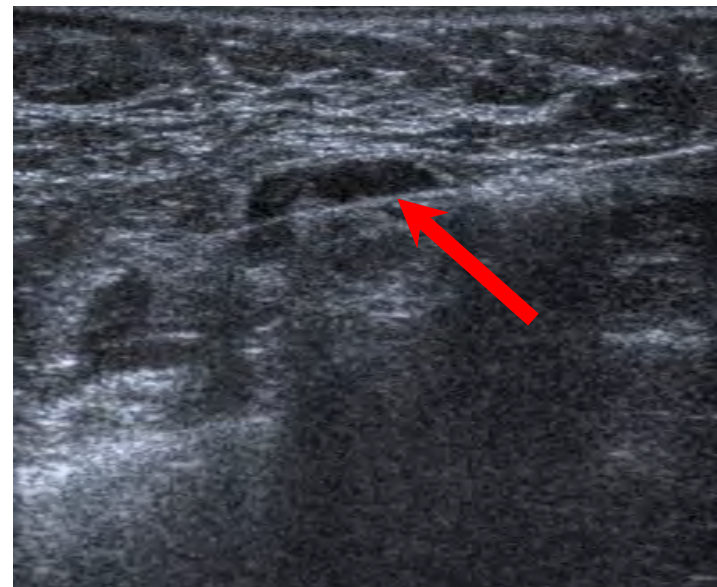Test Your Knowledge



Intervention in the Axilla



If ultrasound evaluation of the axilla reveals a suspicious finding, percutaneous procedures including ultrasound guided fine needle aspiration (FNA) or ultrasound guided core needle biopsy (CNB) should be performed to substantiate clinical decision making.



Biopsy needle through a lymph node cortex.

Chapter Outline

Breast Anatomy

Anatomical Variants

Pregnancy and Lactation

Diagnostic Imaging Techniques

Disease of the Breast: Benign

Disease of the Breast: Malignant

▶ Axilla
▶ Intervention

Interventional Procedures

Screening

High Risk Women

Communication

Multidisciplinary Team Meeting


Take-Home Messages

References

Test Your Knowledge



Interventional Procedures



- Percutaneous image-guided needle biopsy is part of the so called “diagnostic triad” in breast imaging together with mammography and ultrasound. It is essential in the management of suspicious breast lesions detected by screening or during assessment of clinical abnormalities. It is safe and cost effective, allowing accurate decision making, including treatment planning.
- The most appropriate image guide is chosen by radiologist (whenever a lesion is seen on ultrasound, this technique is preferred!)
- Different percutaneous image-guided techniques are available
 1. Fine-Needle Aspiration Cytology (FNAC) → providing material to study cells
 2. Core Needle Biopsy (CNB)
 3. Vacuum-Assisted Biopsy (VAB)

} providing material to study tissue
- Indications: →
 - BI-RADS Category 4A: >2% but ≤10% likelihood of malignancy
 - BI-RADS Category 4B: >10% but ≤50% likelihood of malignancy
 - BI-RADS Category 4C: >50% but <95% likelihood of malignancy
 - BI-RADS Category 5 : >95% likelihood of malignancy

Chapter Outline

- Breast Anatomy
- Anatomical Variants
- Pregnancy and Lactation
- Diagnostic Imaging Techniques
- Disease of the Breast: Benign
- Disease of the Breast: Malignant
- Axilla
- ▶ Interventional Procedures
- Screening
- High Risk Women
- Communication
- Multidisciplinary Team Meeting
- Take-Home Messages
- References
- Test Your Knowledge



Fine Needle Aspiration Cytology



Fine Needle Aspiration Cytology (FNAC) provides material for studying cells allowing a cytological examination

- **Principle:** usually performed under US guidance with a 27-18 gauge fine needle that is inserted very close to US probe. Once the needle is in the target, manual multidirectional sampling is performed, through aspiration using 10-20 ml syringe or simple by manual movement of the needle inside for about 10-20 sec. The extracted material is spread onto slides and fixed in formalin for analysis

Indications:

- Drainage of complicated cysts, seromas, hematomas
- For therapeutic purposes
 - pain relief from swelling cysts, therapy of lactational and non lactational breast abscesses
- Currently discouraged for diagnostic purposes for the lack of molecular information and inadequate rate

Advantages:

- Easy, safe and fast procedure
- Cost and availability

Disadvantages:

- No histopathological analysis
- High rates of inadequate or false negative results



False negative rate ranges up to 20%



Chapter Outline

Breast Anatomy

Anatomical Variants

Pregnancy and Lactation

Diagnostic Imaging Techniques

Disease of the Breast: Benign

Disease of the Breast: Malignant

Axilla

▶ **Interventional Procedures**

▶ FNAC

Screening

High Risk Women

Communication

Multidisciplinary Team Meeting

Take-Home Messages

References

Test Your Knowledge



Core Needle Biopsy



Core Needle Biopsy (CNB) provides material for histopathological analysis

- **Principle:** usually performed under US guidance with a needle from 16 to 12 gauge (recommended 14 gauge). Using an aseptic technique and after local anaesthesia administered through subcutaneous injections (lidocaine/mepivacaine) the needle is inserted, through a small skin incision. Once the needle is in the target a number of cores (3-5) are obtained to document the correct needle positioning. The extracted material is placed in formalin. Post interventional marker clip must be deployed in patients undergoing neoadjuvant treatment or upon radiologist indication.

Indications:

- Suspicious (BI-RADS 4a,4b,4c-5) lesions seen at US
- Axillary lymph nodes assessment

Advantages:

- Easy, safe and fast procedure
- Cost and availability

Disadvantages:

- Subsequent samples imply needle extractions
- False negative rate 1.2-3.3%

False negative rate ranges from 1.2 to 3.3% (mean 2%)



Chapter Outline

Breast Anatomy

Anatomical Variants

Pregnancy and Lactation

Diagnostic Imaging Techniques

Disease of the Breast: Benign

Disease of the Breast: Malignant

Axilla

▶ **Interventional Procedures**
▶ CNB

Screening

High Risk Women

Communication

Multidisciplinary Team Meeting


Take-Home Messages

References

Test Your Knowledge



Vacuum-Assisted Biopsy



Vacuum-Assisted Biopsy provides material for histopathological analysis

- **Principle:** performed with a needle from 12 to 7 gauge, after local anaesthesia under mammography/tomosynthesis/CEM, US and MRI guidance. A special needle connected to a vacuum-generating device is inserted, through a small skin incision. Once the needle is in the target the vacuum attracts the tissue towards the needle and a rotating device cuts the samples remaining in site. Post interventional marker placement is encouraged.

Indications:

- Suspicious microcalcifications or architectural tissue distortion on mammography/tomosynthesis
- Contrast-enhancing lesions on MRI, not visible with conventional imaging
- Radiologic-pathologic discordance after CNB

Advantages:

- Rapid removal of larger amount of tissue (1g)
- Multiple samples without removing the needle
- Risk of lesion displacement reduced

Disadvantages:

- Moderate rate of complications
- Cost and availability (MRI and CEM guidance)



False negative rate ranges from 1.2 to 3.3% (mean 2%)

Chapter Outline

Breast Anatomy

Anatomical Variants

Pregnancy and Lactation

Diagnostic Imaging Techniques

Disease of the Breast: Benign

Disease of the Breast: Malignant

Axilla

▶ **Interventional Procedures**

▶ VAB

Screening

High Risk Women

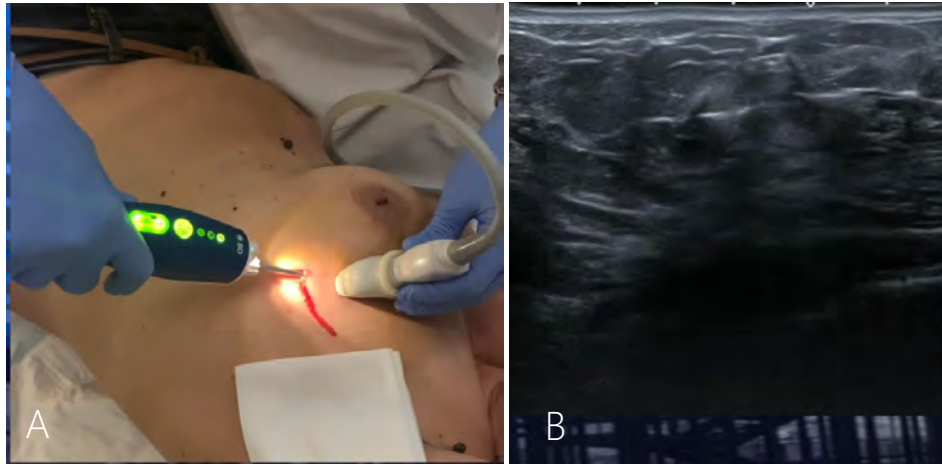
Communication

Multidisciplinary Team Meeting

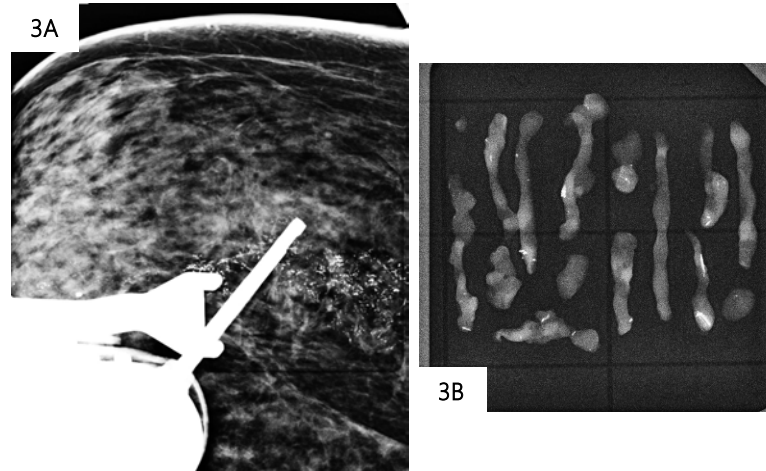
Take-Home Messages

References

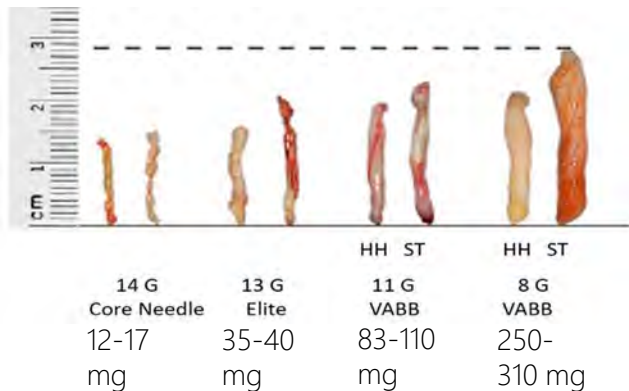
Test Your Knowledge



US-VABB. Ultrasound-guided vacuum assisted breast biopsy. The patient is in supine position. After local anesthesia the VABB device is inserted through the skin toward the target by means of US guidance (1A). The needle is working under the lesion and can take multiple samples without being removed from the breast (1B).



Tomosynthesis-VABB. The patient is in prone position on the dedicated horizontal table. The location of the lesion is calculated through the system and the needle is automatically brought to the exact position (3A, post-fire 2D image). Radiography of the specimens shows the presence of microcalcifications and confirms the adequate sampling (3B). Histological examination revealed a poorly differentiated G3 in situ ductal carcinoma.



Average weight and size of biopsy samples obtained with different needle gauges. (Adapted from La Forgia et al, Diagnostics, 2020).

The most important step to avoid false negative results is systematic radiologic-pathologic correlation



Chapter Outline

- Breast Anatomy
- Anatomical Variants
- Pregnancy and Lactation
- Diagnostic Imaging Techniques
- Disease of the Breast: Benign
- Disease of the Breast: Malignant
- Axilla
- ▶ **Interventional Procedures**
 - ▶ VAB
- Screening
- High Risk Women
- Communication
- Multidisciplinary Team Meeting
- Take-Home Messages
- References
- Test Your Knowledge



Vacuum-Assisted Excision



Vacuum-Assisted Excision (VAE) has the aim to manage in a minimally invasive way selected breast lesions

- Technique : VABB devices with a collection of approximately 4 g of tissue (12-18 x 7 Gauge cores)

Indications:

B3 lesions found at first-attempt diagnostic VAB.

The practice across Europe and UK regarding the role of VAE in managing B3 lesions remains variable.

In 2016, the first international guidelines from Europe were published regarding the management of B3 lesions, and this was recently updated in 2019. For details refer to these documents.

Advantages:

- Reduced surgery
- Reduced hospitalization and cost
- Better cosmetic results
- Reduced risk of complications

Disadvantages:

- Underestimation of malignancy in excised B3 lesions ranges from about 10 to 35%

Chapter Outline

Breast Anatomy

Anatomical Variants

Pregnancy and Lactation

Diagnostic Imaging Techniques

Disease of the Breast: Benign

Disease of the Breast: Malignant

Axilla

▶ **Interventional Procedures**

▶ VAE

Screening

High Risk Women

Communication

Multidisciplinary Team Meeting

Take-Home Messages

References

Test Your Knowledge



Pre-Operative Image-Guided Localisation



Non palpable breast lesions need image-guided preoperative localization, allowing for a safe and effective complete removal (clear margins) and cosmetic result. There is no clear evidence to support one guided technique over another with similar feasibility rate. Local policies and resources guide the choice.

Current options

- **Carbon marking**
Long standing methods. Surgery up to 1 month after.
- **Wire localisation** Most commonly used method
Safe and cost effective. Surgery within 24 h after. Possible rupture/migration
- **Radio-guided localisation**
Surgery within 24 h after. Radiation exposure. Higher cost and complex logistics
- **Radioactive seed localisation**
Longer interval time admitted between procedure and surgery. Radiation exposure. Higher cost
- **Magnetic seed localisation**
Surgery up to 1 month after. Higher cost. Artefact in Breast MRI.



Chapter Outline

Breast Anatomy

Anatomical Variants

Pregnancy and Lactation

Diagnostic Imaging Techniques

Disease of the Breast: Benign

Disease of the Breast: Malignant

Axilla

▶ **Interventional Procedures**
▶ Pre-Operative Localisation

Screening

High Risk Women

Communication

Multidisciplinary Team Meeting

Take-Home Messages

References

Test Your Knowledge



Minimal Invasive Therapy: a Goal for the Future



These treatments can achieve local tumour ablation through various types of energy that destroy tumour cells in different ways

- Radiofrequency
 - Microwaves
 - Laser ablation
- } Electromagnetic waves
- Cryoablation → Cooling
 - High-intensity focus ultrasound (HIFU) → Mechanical waves

Potential Indications:

- Small tumours (early breast cancer)
- Benign breast lesions
- Contraindications to general anaesthesia
- Older patients (comorbidities)
- Palliative approach
- Patients who refuse surgery

Potential advantages:

- Local anaesthesia
- Reduced hospitalization and cost
- Better cosmetic results
- Reduced risk of complications

Limitations:

- Lack of pathological examination of the entire lesion
- Large/multicentric tumours
- Tumours close to skin/muscle

Chapter Outline

Breast Anatomy

Anatomical Variants

Pregnancy and Lactation

Diagnostic Imaging Techniques

Disease of the Breast: Benign

Disease of the Breast: Malignant

Axilla

▶ **Interventional Procedures**
▶ Minimal Invasive Therapy

Screening

High Risk Women

Communication

Multidisciplinary Team Meeting


Take-Home Messages

References

Test Your Knowledge



Why screen? -The Basics



- Early cancer detection increases the probability of successful treatment.
- The aim of breast cancer screening programmes is to reduce breast cancer mortality by early detection and early treatment of asymptomatic cancer
- Screening mammography in national screening programmes includes mammography performed every 1, 2 or 3 years from the age of 40–50 years until around 70–75



- European guidelines suggest the 2-year interval for the general female population from 50 to 70 years of age & every 2 or 3 years for women aged 45 to 49 years.

Chapter Outline

Breast Anatomy

Anatomical Variants

Pregnancy and Lactation

Diagnostic Imaging Techniques

Disease of the Breast: Benign

Disease of the Breast: Malignant

Axilla

Interventional Procedures

▶ Screening

High Risk Women

Communication

Multidisciplinary Team Meeting

Take-Home Messages

References

Test Your Knowledge



Wilson & Junger Outlined 10 Criteria for Screening



1. The condition screened for should be an IMPORTANT one
2. There should be an ACCEPTABLE TREATMENT for the disease
3. DIAGNOSTIC & TREATMENT facilities should be available
4. A RECOGNISABLE LATENT or EARLY SYMPTOMATIC stage is required
5. There should be an AGREED POLICY on who to treat
6. The test must be of HIGH DISCRIMINATORY POWER, VALID (measuring what it proposes to measure) & be REPRODUCIBLE
7. The test must be ACCEPTABLE to the client being screened
8. The NATURAL HISTORY of the untreated disease should be adequately understood
9. The COST of case-finding (diagnosing and treating patients diagnosed) should be economically balanced in relation to possible expenditure on medical care as a whole
10. Screening is a CONTINUOUS PROCESS

Chapter Outline

Breast Anatomy

Anatomical Variants

Pregnancy and Lactation

Diagnostic Imaging Techniques

Disease of the Breast: Benign

Disease of the Breast: Malignant

Axilla

Interventional Procedures

▶ Screening

High Risk Women

Communication

Multidisciplinary Team Meeting

Take-Home Messages

References

Test Your Knowledge



A **risk factor** is defined as anything that affects an individual's chance of getting a disease.

Certain major risk factors for breast cancer are beyond an individual's control.

Simply **being a woman** is the main risk factor for breast cancer. Breast cancer is about 100 times more likely to occur in women than in men.

Aging inevitably increases the risk of developing breast cancer. Almost 8 out of 10 women diagnosed are over the age of 50. Breast cancer is rare in women under 30 years old.

Chapter Outline

Breast Anatomy

Anatomical Variants

Pregnancy and Lactation

Diagnostic Imaging Techniques

Disease of the Breast: Benign

Disease of the Breast: Malignant

Axilla

Interventional Procedures

▶ **Screening**
▶ Risk Factors

High Risk Women

Communication

Multidisciplinary Team Meeting

Take-Home Messages

References

Test Your Knowledge



Factors Associated with an Increased Risk of Breast Cancer



- Family history
- Early menarche (age < 12 years)
- Late first pregnancy (after age 28 years)
- Current use of an Oral Contraceptives Pill (OCP) and for 10 years later Nulliparity
- Late menopause
- Prolonged use of Hormone Replacement Therapy (HRT)
- Significant weight gain in adult life
- Sedentary lifestyle
- Increased mammographic breast density

Chapter Outline

Breast Anatomy

Anatomical Variants

Pregnancy and Lactation

Diagnostic Imaging Techniques

Disease of the Breast: Benign

Disease of the Breast: Malignant

Axilla

Interventional Procedures

▶ Screening

▶ Risk Factors

High Risk Women

Communication

Multidisciplinary Team Meeting

Take-Home Messages

References

Test Your Knowledge



AGE & Risk of Breast CANCER



Risk up to and including age 29 years	1 in 2000
Risk up to and including age 39 years	1 in 315
Risk up to and including age 49 years	1 in 50
Risk up to and including age 59 years	1 in 22
Risk up to and including age 69 years	1 in 13
LIFETIME RISK	1 in 8

Chapter Outline

Breast Anatomy

Anatomical Variants

Pregnancy and Lactation

Diagnostic Imaging Techniques

Disease of the Breast: Benign

Disease of the Breast: Malignant

Axilla

Interventional Procedures

▶ Screening

▶ Risk Factors

High Risk Women

Communication

Multidisciplinary Team Meeting

Take-Home Messages

References

Test Your Knowledge

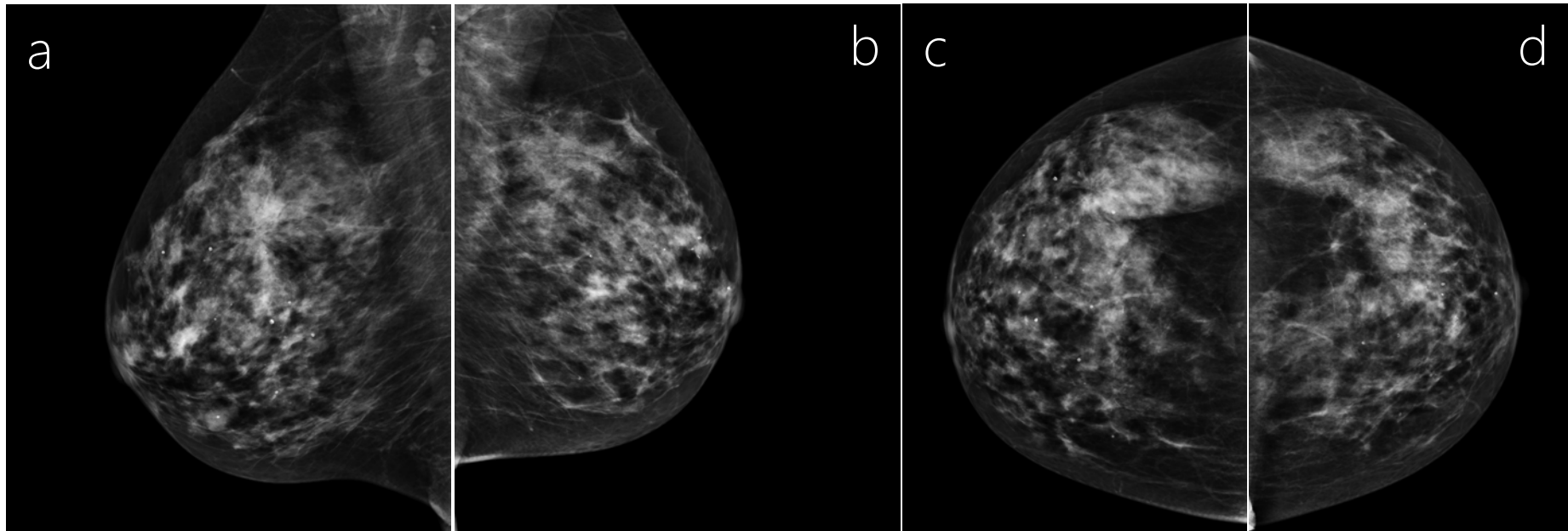


How to Screen?



Studies show that even when women have access to the latest therapies deaths from breast cancer decline at a much higher rate than women who get mammographic screening.

Screening test: THE MAMMOGRAM (direct digital acquisition)



- 4 VIEWS: Right & Left Mediolateral oblique views (a,b) AND BilateralCraniocaudal views (c,d). Breast compressed between paddles.

Chapter Outline

Breast Anatomy

Anatomical Variants

Pregnancy and Lactation

Diagnostic Imaging Techniques

Disease of the Breast: Benign

Disease of the Breast: Malignant

Axilla

Interventional Procedures

▶ Screening
▶ How to Screen

High Risk Women

Communication

Multidisciplinary Team Meeting

Take-Home Messages

References

Test Your Knowledge



Limitations of Breast Screening



- Interval cancer and false positive recalls
 - Cancer may still develop in between one screening round and the next. Any symptoms which develop in the interim should not be dismissed without workup.
 - A number of screening clients may undergo additional tests (additional mammo views, ultrasonography with or without needle sampling) - and associated worry - which result in a benign diagnosis. The average risk of false positive recall of clients undergoing biennial screening aged 50-69 years has been calculated at 20%.
- “Overdiagnosis”
 - Some screen-detected breast cancers would have never otherwise been found and would not have become life-threatening. There is as yet no way to identify which breast cancers are not life-threatening and treatment is offered for all diagnosed breast cancers.

Chapter Outline

Breast Anatomy

Anatomical Variants

Pregnancy and Lactation

Diagnostic Imaging Techniques

Disease of the Breast: Benign

Disease of the Breast: Malignant

Axilla

Interventional Procedures

▶ **Screening**
▶ Limitations of Screening

High Risk Women

Communication

Multidisciplinary Team Meeting

Take-Home Messages

References

Test Your Knowledge



Limitations of Breast Screening



- Radiation penalty
 - Mammography involves exposure of the breast tissue to ionising radiation (which is potentially carcinogenic)
 - The effective dose for standard 2-view mammogram of each breast is 0.4mSV for digital mammography. (This may be comparable to 2 months of background radiation quoted at 3mSV per annum or the equivalent of under a third of the effective dose from a lumbosacral spine radiograph).
 - The small risk of radiation-induced cancer in an organised and controlled breast screening programme is outweighed by the benefits of expected mortality reduction.
- Mammography of Dense Breasts
 - Breast density is the measure of the proportion of glandular tissue Vs fatty tissue in a breast on mammography. The similar x ray absorption of fibroglandular tissue and breast cancers results in potential masking of breast cancers on mammography in denser breasts.

Chapter Outline

Breast Anatomy

Anatomical Variants

Pregnancy and Lactation

Diagnostic Imaging Techniques

Disease of the Breast: Benign

Disease of the Breast: Malignant

Axilla

Interventional Procedures

▶ **Screening**
▶ Limitations of Screening

High Risk Women

Communication

Multidisciplinary Team Meeting

Take-Home Messages

References

Test Your Knowledge



High Risk Women



- All national breast cancer screening programs offer the same imaging to every eligible woman except where there is evidence of increased risk factors for developing breast cancer.
- Risk for breast cancer is calculated based on age, genetic testing, family history of breast and ovarian cancer, and clinical history (personal history of breast cancer, chest radiation, history of a breast biopsy with atypical epithelial proliferations in the breast, and extremely dense breasts
- Women can be classified as being at average, intermediate and high lifetime risk of developing breast cancer.
- Women at *average risk* are considered those with a lifetime risk developing breast cancer of <15%
- Women at *intermediate risk* are considered those with a lifetime risk developing breast cancer ranged between 15% and 20%, a personal history of breast cancer, dense breasts at mammography or a history of high-risk lesions at biopsy (specifically, atypical ductal hyperplasia, atypical lobular hyperplasia, and lobular carcinoma in situ)
- Women at *high risk* are considered those with a lifetime risk developing breast cancer of >20%

Chapter Outline

Breast Anatomy

Anatomical Variants

Pregnancy and Lactation

Diagnostic Imaging Techniques

Disease of the Breast: Benign

Disease of the Breast: Malignant

Axilla

Interventional Procedures

Screening

▶ **High Risk Women**
▶ Introduction

Communication

Multidisciplinary Team Meeting

Take-Home Messages

References

Test Your Knowledge

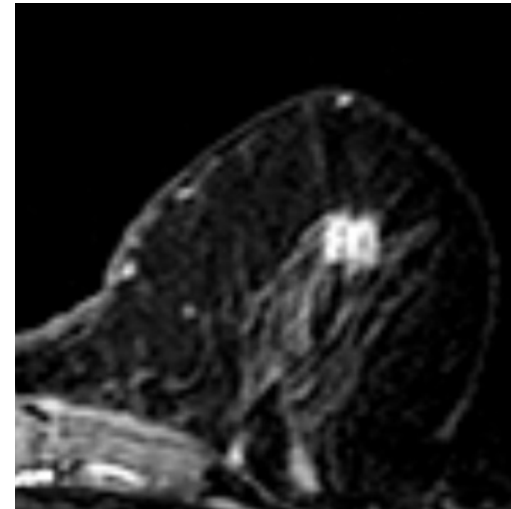
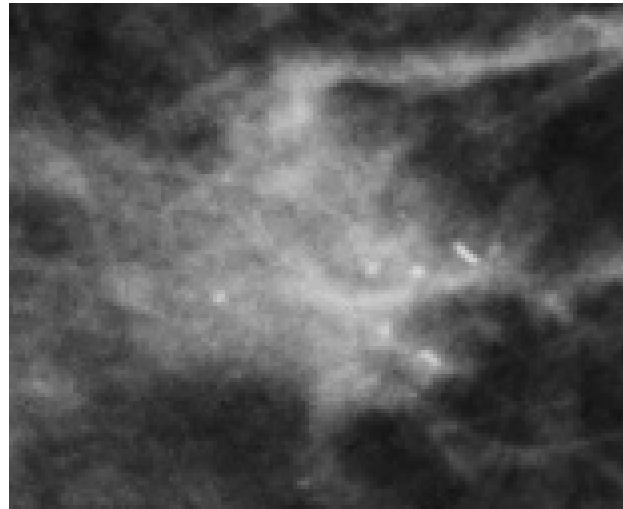
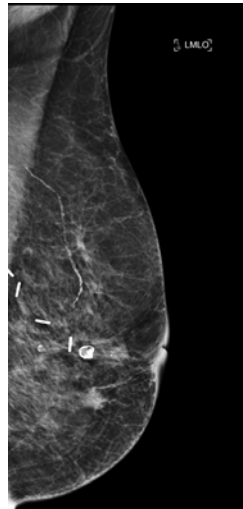


Personal History of Breast Cancer: Screening



Women with a personal history of breast cancer are at a substantially increased risk for the development of a recurrence or second breast cancer.

The sensitivity of mammography for early detection of second breast cancers is slightly reduced due to postoperative changes, including scar formation and dystrophic calcifications



- Annual breast MRI as an adjunct to mammography for women with a previous breast cancer diagnosis at an age younger than 50 years is now recommended in the USA.

Chapter Outline

Breast Anatomy

Anatomical Variants

Pregnancy and Lactation

Diagnostic Imaging Techniques

Disease of the Breast: Benign

Disease of the Breast: Malignant

Axilla

Interventional Procedures

Screening

▶ High Risk Women
▶ History

Communication

Multidisciplinary Team Meeting

Take-Home Messages

References

Test Your Knowledge



History of Atypical Epithelial Proliferations in the Breast



Women with history of atypical epithelial proliferation such as atypical ductal hyperplasia (ADH), atypical lobular hyperplasia (ALH), and lobular carcinoma in situ (LCIS) have a relative risk of 3 to 10 times higher of developing breast cancer compared with the general population

- If left in the breast, these lesions might develop into a ductal carcinoma in situ (DCIS) or invasive carcinoma although the progression to malignancy is low and occurs over a long period (PPV 10-15%);
- The risk to develop breast cancer in the same or contralateral breast is respectively 3.8% to 3.7% at 10 years, 8.9% to 8.6% at 15 years and 30.5% to 26.2% at 25 years from the diagnosis.

Chapter Outline

Breast Anatomy

Anatomical Variants

Pregnancy and Lactation

Diagnostic Imaging Techniques

Disease of the Breast: Benign

Disease of the Breast: Malignant

Axilla

Interventional Procedures

Screening

▶ High Risk Women

▶ History

Communication

Multidisciplinary Team Meeting

Take-Home Messages

References

Test Your Knowledge

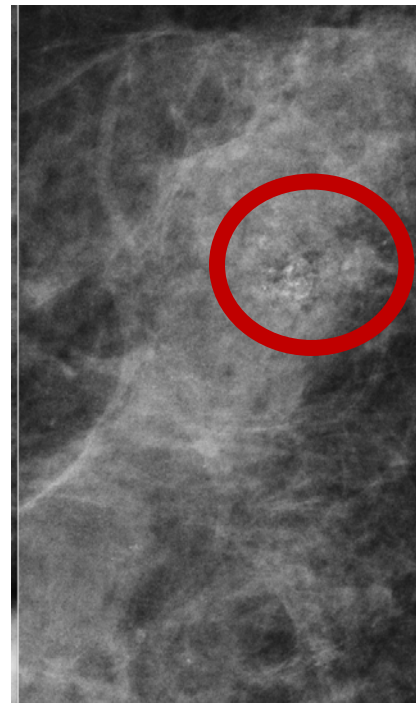


History of Atypical Epithelial Proliferations in the Breast: Screening

HIGH RISK LESION	IMAGING FINDINGS
Atypical Ductal Hyperplasia (ADH)	Fine pleomorphic microcalcifications and linear or segmental distribution. As an irregular-shaped small hypoechoic mass with micro-lobulated edges.
Lobular Neoplasia (LN)	Amorphous microcalcifications and grouped distribution.



Currently, annual screening mammography with consideration for annual MRI in women with history of atypia, especially if other risk factors are present is indicated



Atypical Ductal Hyperplasia (ADH)

Modified from Catanzariti F. et al (2021)

Chapter Outline

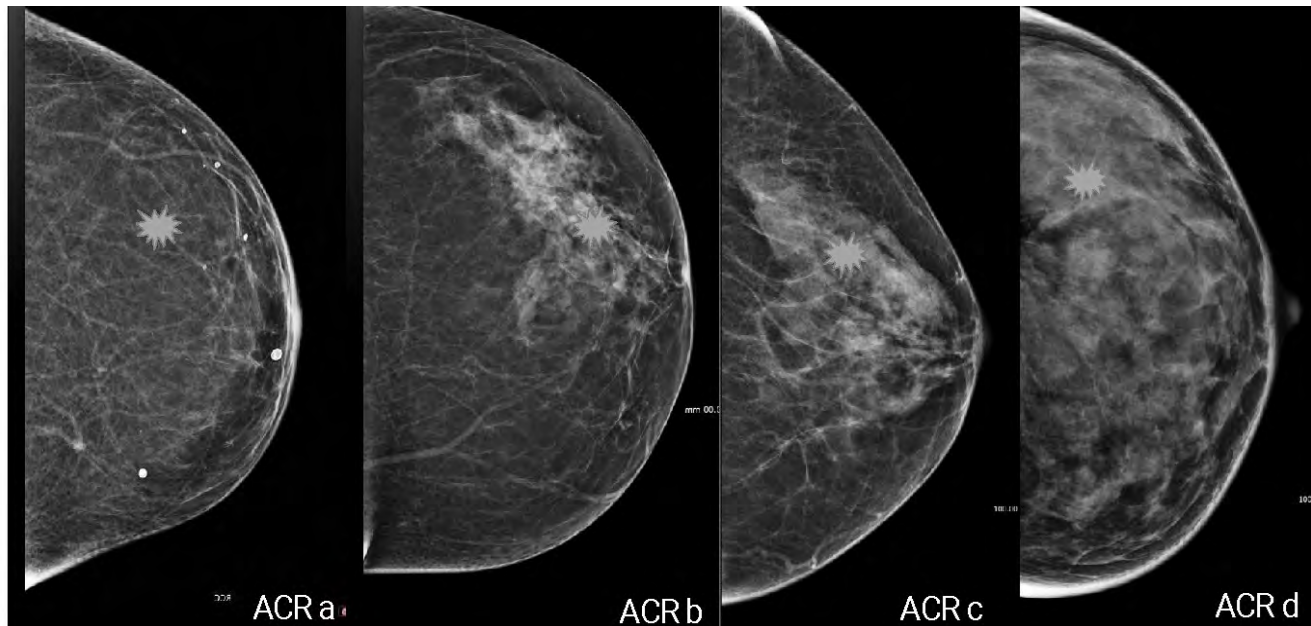
- Breast Anatomy
- Anatomical Variants
- Pregnancy and Lactation
- Diagnostic Imaging Techniques
- Disease of the Breast: Benign
- Disease of the Breast: Malignant
- Axilla
- Interventional Procedures
- Screening
- ▶ High Risk Women
 - ▶ History
- Communication
- Multidisciplinary Team Meeting
- Take-Home Messages
- References
- Test Your Knowledge



Extremely Dense Breast: Masking Effect



The fibro-glandular tissue, commonly referred as “dense tissue”, absorbs ionizing radiation and projects *white* on mammography like most cancers that appear *white* on mammography.



Cancers could therefore be hidden by dense (*white*) tissue.

This means that dense tissue may prevent- “mask”- the detection on mammography.

This is the so called “masking effect”



Chapter Outline

Breast Anatomy

Anatomical Variants

Pregnancy and Lactation

Diagnostic Imaging Techniques

Disease of the Breast: Benign

Disease of the Breast: Malignant

Axilla

Interventional Procedures

Screening

▶ High Risk Women

▶ Density

Communication

Multidisciplinary Team Meeting

Take-Home Messages

References

Test Your Knowledge



Extremely Dense Breast: Independent Risk Factor



Besides the risk of masking breast cancer, breast density is also one of the strongest known **independent risk factor** for developing breast cancer.

- Dense breast tissue is common in women, with 31%-43% of the general screening population having heterogeneously dense (c) or extremely dense breasts (d) on mammography
- Women with extremely dense breast (d) had a 4.6-fold increased breast cancer risk (95% confidence interval, 3.6-5.9) compared with women with fatty breasts.
- This is due to both the absolute higher amount of fibro-glandular tissue within the breast and the breast composition.

Chapter Outline

Breast Anatomy

Anatomical Variants

Pregnancy and Lactation

Diagnostic Imaging Techniques

Disease of the Breast: Benign

Disease of the Breast: Malignant

Axilla

Interventional Procedures

Screening

▶ High Risk Women

▶ Density

Communication

Multidisciplinary Team Meeting

Take-Home Messages

References

Test Your Knowledge



Extremely Dense Breast: Screening



In women with extremely dense breast tissue the sensitivity of digital mammography (DM) screening is about 62–68% compared to 86 to 89% in women with fatty breasts.

The use of digital breast tomosynthesis (DBT) has increased the cancer detection rates by 20 to 40% in women with dense breasts.

However, both DM and DBT seem to be heavily affected by breast density and thus lead to underdiagnosis of relevant cancers in these women

The added value of supplemental ultrasound regarding cancer detection is limited, especially concerning the high number of false positive examinations

Chapter Outline

Breast Anatomy

Anatomical Variants

Pregnancy and Lactation

Diagnostic Imaging Techniques

Disease of the Breast: Benign

Disease of the Breast: Malignant

Axilla

Interventional Procedures

Screening

▶ **High Risk Women**
▶ Density

Communication

Multidisciplinary Team Meeting

Take-Home Messages

References

Test Your Knowledge



Extremely Dense Breast: Screening



The European Society of Breast Imaging (ESOBi) now recommends:

- Women with extremely dense breasts should be appropriately informed about their density and on the diagnostic and prognostic implication of having dense breasts
- Supplemental screening with breast MRI or breast MRI alone should be offered to women with extremely dense breast from age 50 to 70 years should preferably every 2 to 3 years
- Supplemental ultrasound to mammography should be offered to women with dense breasts as an alternative to breast MRI when the MRI screening is not available

Chapter Outline

Breast Anatomy

Anatomical Variants

Pregnancy and Lactation

Diagnostic Imaging Techniques

Disease of the Breast: Benign

Disease of the Breast: Malignant

Axilla

Interventional Procedures

Screening

▶ High Risk Women

▶ Density

Communication

Multidisciplinary Team Meeting

Take-Home Messages

References

Test Your Knowledge



High Risk Women



High-Risk are women with a lifetime risk equal to or higher than 20% of developing breast cancer in their life.

This includes women with:

- Hereditary breast cancer
- Familial Risk of breast and ovarian cancer
- History of chest wall radiation at a young age

Chapter Outline

Breast Anatomy

Anatomical Variants

Pregnancy and Lactation

Diagnostic Imaging Techniques

Disease of the Breast: Benign

Disease of the Breast: Malignant

Axilla

Interventional Procedures

Screening

▶ **High Risk Women**

▶ High Risk

Communication

Multidisciplinary Team Meeting


Take-Home Messages

References

Test Your Knowledge



Hereditary Breast Cancer



- Women diagnosed with breast cancers are carriers of a known genetic mutation in about 5-10% of cases
- The presence of a BRCA1 or BRCA2 mutation accounts for the majority of hereditary breast and ovarian cancer syndromes
- Other rarer gene mutations include TP53, PTEN, PALB2, STK11, CDH1, ATM, and CHECK2.
- More than 2000 different mutations have been identified in BRCA1/2 genes, and in some populations—for example in Ashkenazi Jewish- the prevalence of a BRCA 1 or BRCA2 mutation is higher

Chapter Outline

Breast Anatomy

Anatomical Variants

Pregnancy and Lactation

Diagnostic Imaging Techniques

Disease of the Breast: Benign

Disease of the Breast: Malignant

Axilla

Interventional Procedures

Screening

▶ **High Risk Women**
▶ High Risk

Communication

Multidisciplinary Team Meeting

Take-Home Messages

References

Test Your Knowledge



Hereditary and Familial Risk



Women diagnosed with a genetic mutation carry a breast cancer risk that is different for each mutation:

- For BRCA1 • 75–82%;
- For BRCA2 • 76–82%;
- For TP53 • 95% by 90 years old;
- For PTEN • 85% by 80 years old;
- For CDH1 • 53% by 80 years old;
- For STK11 • 32% by 60 years old;

Among *men* harboring a BRCA1 or BRCA2 mutation, there is an estimated lifetime risk of breast cancer of 1.2% to $\leq 8\%$, respectively and a doubling of prostate cancer risk.

Chapter Outline

Breast Anatomy

Anatomical Variants

Pregnancy and Lactation

Diagnostic Imaging Techniques

Disease of the Breast: Benign

Disease of the Breast: Malignant

Axilla

Interventional Procedures

Screening

▶ High Risk Women
▶ High Risk

Communication

Multidisciplinary Team Meeting

Take-Home Messages

References

Test Your Knowledge



Familial Risk of Breast and Ovarian Cancer



- Patients with the following family histories of cancer, all on the same side of the family, are at increased risk and should be referred to Clinical Genetics:
 - Three or more 1st or 2nd degree relatives with breast and / or ovarian cancer;
 - One 1st and one 1st or 2nd degree relative both with breast cancer or one with breast cancer and one with ovarian cancer;
 - Two 1st or 2nd degree relatives with ovarian cancer or one 1st or 2nd degree relative with breast cancer and one 1st or 2nd degree relative with either a sarcoma < 45, a glioma or a childhood adrenal cortical carcinoma;
 - A 1st degree relative with breast cancer under 40, or triple negative breast cancer under 60.
 - A 1st degree relative with bilateral breast cancer or with male breast cancer or with both breast and ovarian cancer.
 - Ashkenazi Jewish heritage with a 1st degree relative with breast cancer or ovarian cancer at any age
- In the absence of a genetic mutation, the risk for women with a strong family history of breast cancer remains high, although somewhat lower compared to the one in whom a germline mutation is found

Chapter Outline

Breast Anatomy

Anatomical Variants

Pregnancy and Lactation

Diagnostic Imaging Techniques

Disease of the Breast: Benign

Disease of the Breast: Malignant

Axilla

Interventional Procedures

Screening

▶ High Risk Women

▶ High Risk

Communication

Multidisciplinary Team Meeting

Take-Home Messages

References

Test Your Knowledge



High Risk Women: Screening



- For high-risk women, national and international guidelines are in favour of including dedicated pathways for screening, offering breast magnetic resonance imaging (MRI);
- International guidelines recommend screening high-risk women with yearly MRI from age 25 years onwards, and additional mammography from age 30 years;
- Due to the high tumour growth rate and shorter lead time of BRCA-related breast cancers, alternating MR imaging and mammographic screening examinations at 6-month intervals also may be a clinically effective approach.
- BRCA1/BRCA2 can choose between prophylactic bilateral mastectomy and ovariectomy, leading to a 90% risk reduction. Alternatively, they join screening programs.

Chapter Outline

Breast Anatomy

Anatomical Variants

Pregnancy and Lactation

Diagnostic Imaging Techniques

Disease of the Breast: Benign

Disease of the Breast: Malignant

Axilla

Interventional Procedures

Screening

▶ **High Risk Women**

▶ High Risk

Communication

Multidisciplinary Team Meeting

Take-Home Messages

References

Test Your Knowledge



History of Chest Wall Radiation at a Young Age



- There is a substantially increased risk of breast cancer following chest irradiation and breast cancer in women is the leading cause of death in long-term survivors of Hodgkin lymphoma
- Estimates of breast cancer are highest among women treated before the age of 30 years, due to the known sensitivity of breast tissue to radiation at younger ages
- The cumulative risk increases with the radiation dose delivered, volume of the radiation field, and time interval since completion of the radiation therapy;
- The incidence of breast cancer increases after approximately 8 years following chest irradiation, and by the age of 40–45 years, 13%–20% of women treated with moderate- to high-dose chest irradiation for a paediatric cancer will be diagnosed with breast cancer

Screening



- Females irradiated below the age of 10 years- additional screening is not applicable to these females.
- Females irradiated between ages of 10 and 19 are eligible for MRI screening annually from age 20 to <71years old. Surveillance starts at 25 or 8 years after first irradiation;
- Females irradiated between ages of 20 and 29 are eligible for MRI screening annually from age 30 to 39 years, and from age 40 to<71 annual MRI and mammographic screening;

Chapter Outline

Breast Anatomy

Anatomical Variants

Pregnancy and Lactation

Diagnostic Imaging Techniques

Disease of the Breast: Benign

Disease of the Breast: Malignant

Axilla

Interventional Procedures

Screening

▶ **High Risk Women**
▶ High Risk

Communication

Multidisciplinary Team Meeting

Take-Home Messages

References

Test Your Knowledge



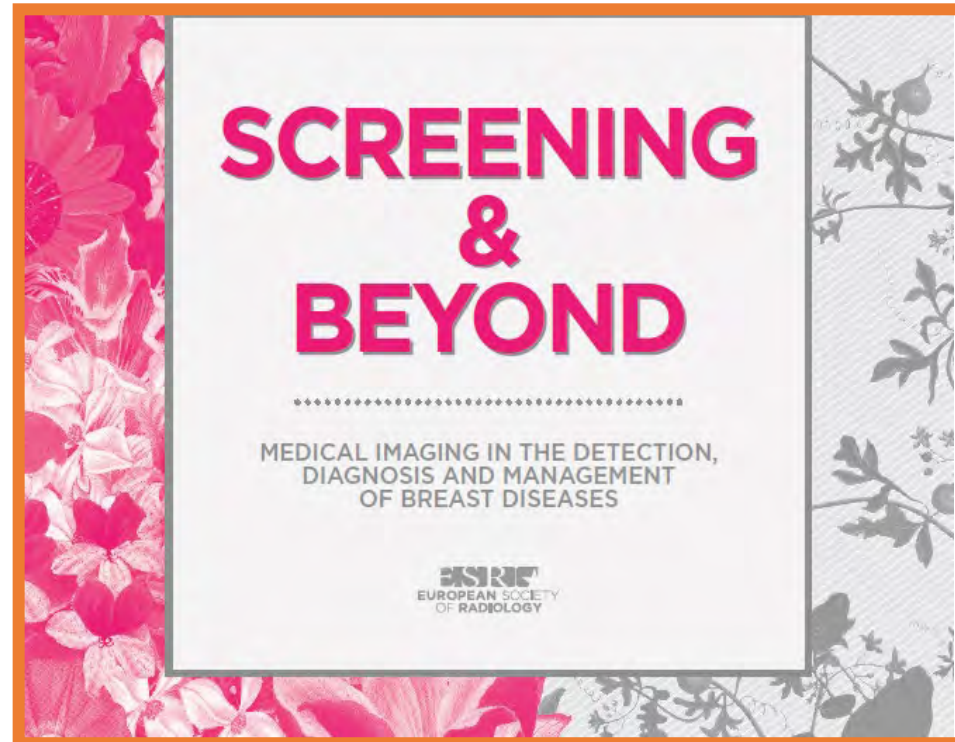
Communication and Attendance to Screening



As breast imaging has become an important subspecialty of radiology, it has evolved into a more clinically oriented discipline

There is far greater need for direct contact and communication with the patient about procedures, diagnoses, management options and follow-up recommendations.

There is now a greater emphasis on the need to understand the potential influences of communication to encourage ongoing participation in screening mammography



In symptomatic patients > 40 years of age – mammographic assessment may be considered the first-line modality for breast assessment

Chapter Outline

- Breast Anatomy
- Anatomical Variants
- Pregnancy and Lactation
- Diagnostic Imaging Techniques
- Disease of the Breast: Benign
- Disease of the Breast: Malignant
- Axilla
- Interventional Procedures
- Screening
- High Risk Women
- ▶ **Communication**
 - ▶ Mammography – Indications and Recommendations
- Multidisciplinary Team Meeting
- Take-Home Messages
- References
- Test Your Knowledge



What should be considered prior to booking a Mammogram appointment?



PREMENOPAUSE

The correct time to schedule an appointment is day 7-12 of menstrual cycle.

Mammographic sensitivity is NOT limited by menstrual cycle – but tolerance of mammographic compression may be increased. Symptomatic patients may consider waiting for their period to see if symptoms are cycle related and may resolve.

Mammography is not performed in pregnancy and lactation.

POSTMENOPAUSAL

No scheduling limitations save for consideration of interim since previous mammographic workup.

If available, patient should take any previous breast imaging copies and reports for comparison.

Chapter Outline

Breast Anatomy

Anatomical Variants

Pregnancy and Lactation

Diagnostic Imaging Techniques

Disease of the Breast: Benign

Disease of the Breast: Malignant

Axilla

Interventional Procedures

Screening

High Risk Women

- ▶ **Communication**
 - ▶ Mammography – Indications and Recommendations

Multidisciplinary Team Meeting

Take-Home Messages

References

Test Your Knowledge



Can a cancer be missed on Mammography?



Mammography is not a perfect test.

Up to 28% of cancers can be missed – particularly in premenopausal women and in those with dense breasts.

Breasts symptoms should be given appropriate consideration despite a recent negative screening mammogram.



Chapter Outline

Breast Anatomy

Anatomical Variants

Pregnancy and Lactation

Diagnostic Imaging Techniques

Disease of the Breast: Benign

Disease of the Breast: Malignant

Axilla

Interventional Procedures

Screening

High Risk Women

- ▶ **Communication**
 - ▶ Mammography – Indications and Recommendations

Multidisciplinary Team Meeting

Take-Home Messages

References

Test Your Knowledge



When is breast ultrasound recommended?



Ultrasound is an established tool for the workup of suspected cancers.

It is the breast imaging method of choice in women under 40 years of age.

The European Society of Breast Imaging (EUSOBI) outlines the following definite indications for Breast Ultrasound

- Palpable lump
- Axillary adenopathy
- First approach for clinical breast abnormalities under age 40Y
- First approach for clinical breast abnormalities in pregnant or lactating women
- Suspicious abnormalities at mammography or MRI
- Suspicious nipple discharge
- Recent nipple inversion
- Skin retraction
- Breast inflammation
- Abnormalities at the surgical scar after breast conserving surgery or mastectomy
- Abnormalities in the presence of Breast Implants
- Screening high-risk women, especially when MRI is not performed
- Guidance for percutaneous breast interventions (needle biopsy, pre-surgical localisation, fluid collection drainage)
- Monitoring patients with breast cancer receiving neo-adjuvant therapy, when MRI is not performed

Chapter Outline

Breast Anatomy

Anatomical Variants

Pregnancy and Lactation

Diagnostic Imaging Techniques

Disease of the Breast: Benign

Disease of the Breast: Malignant

Axilla

Interventional Procedures

Screening

High Risk Women

► **Communication**
► Ultrasound – Indications

Multidisciplinary Team Meeting

Take-Home Messages

References

Test Your Knowledge



Can breast US be performed instead of mammography for breast cancer screening?



Ultrasound may seem as a safe alternative to mammography – as it does not involve exposure to ionising radiation.

However, US has not been shown to reduce mortality from breast cancer in the general female population.

If US is used as a stand-alone screening tool instead of mammography, cancers could be missed, particularly in fatty breasts.

Chapter Outline

Breast Anatomy

Anatomical Variants

Pregnancy and Lactation

Diagnostic Imaging Techniques

Disease of the Breast: Benign

Disease of the Breast: Malignant

Axilla

Interventional Procedures

Screening

High Risk Women

▶ **Communication**
▶ Ultrasound – Indications

Multidisciplinary Team Meeting

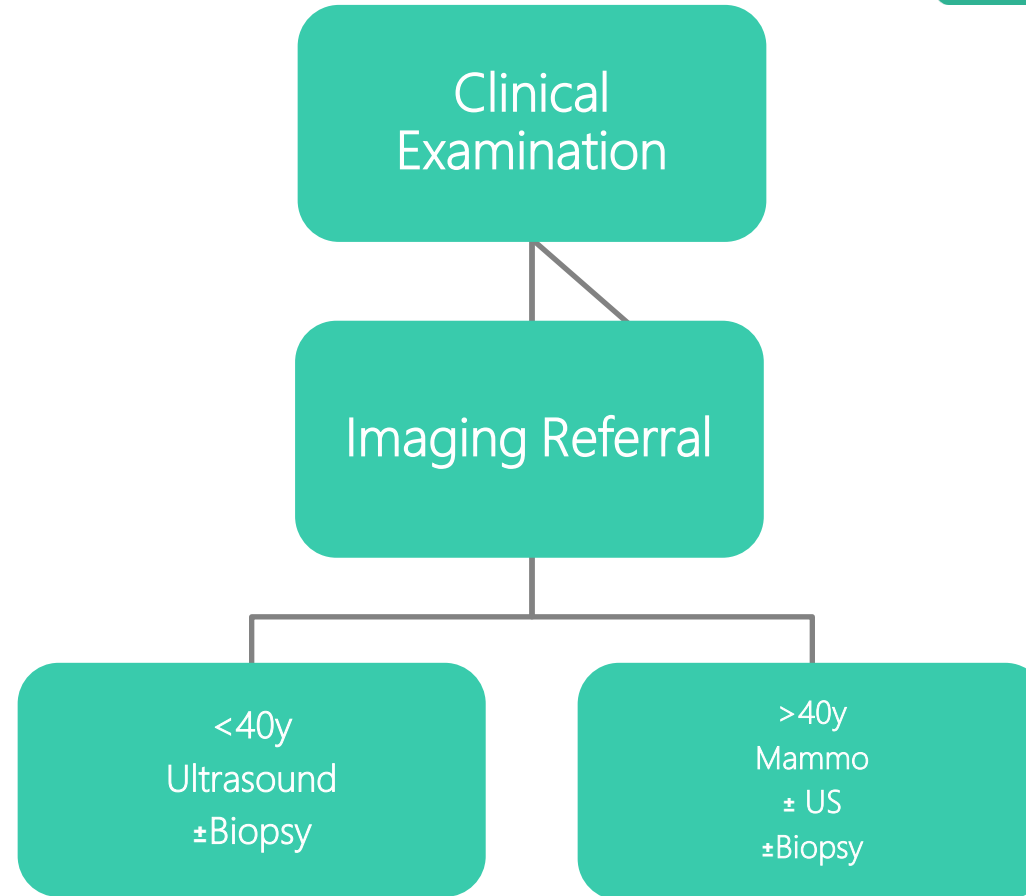
Take-Home Messages

References

Test Your Knowledge



Triple Assessment Schematic of
the Symptomatic Breast Patient –
may be performed as part of a
One Stop Clinic



Chapter Outline

- Breast Anatomy
- Anatomical Variants
- Pregnancy and Lactation
- Diagnostic Imaging Techniques
- Disease of the Breast: Benign
- Disease of the Breast: Malignant
- Axilla
- Interventional Procedures
- Screening
- High Risk Women
- ▶ **Communication**
 - ▶ Triple Assessment
- Multidisciplinary Team Meeting
- Take-Home Messages
- References
- Test Your Knowledge



Breast Imaging Scenarios: Screening & Diagnostic



Imaging of the breast may be

Screening of an asymptomatic cohort of clients assessed to pick up early disease changes

Breast screening is discussed in a dedicated chapter of this e book.

Diagnostic:

Workup of

- A clinical finding eg lump, nipple changes or discharge, skin dimpling, breast inflammation
- An incidental finding (breast finding on CT/MRI/PET Scan performed for a non-breast related indication)

Chapter Outline

Breast Anatomy

Anatomical Variants

Pregnancy and Lactation

Diagnostic Imaging Techniques

Disease of the Breast: Benign

Disease of the Breast: Malignant

Axilla

Interventional Procedures

Screening

High Risk Women

▶ **Communication**
▶ Breast Imaging Scenarios

Multidisciplinary Team Meeting

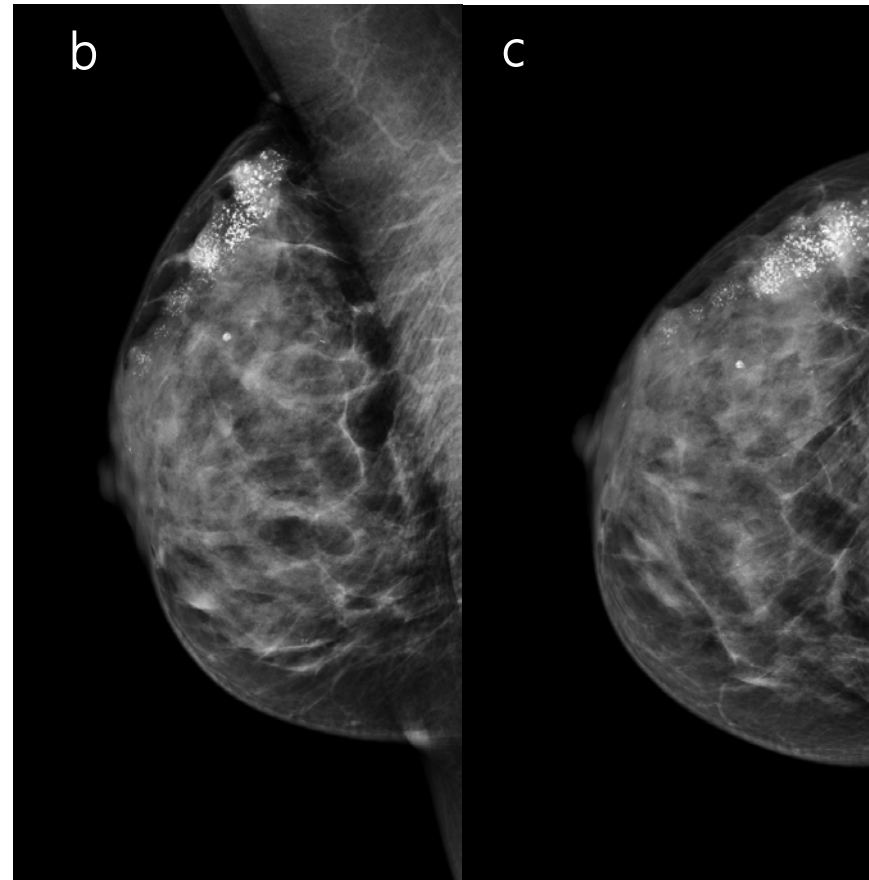
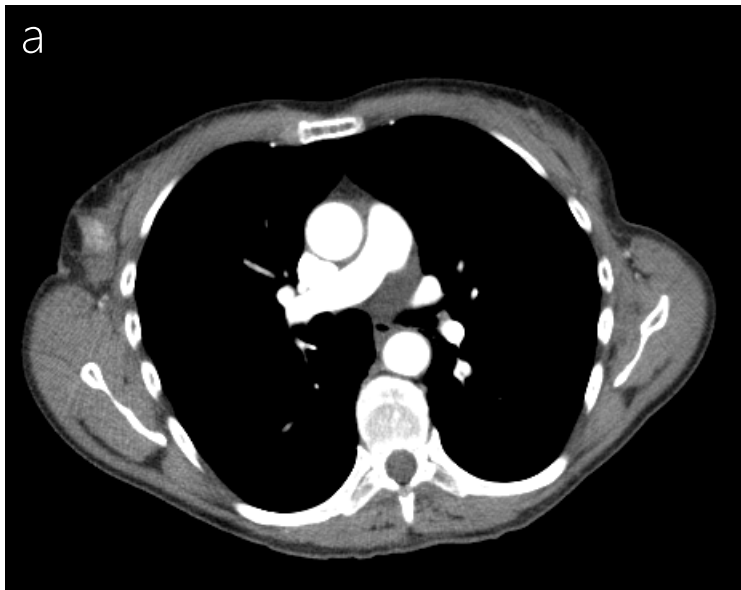
Take-Home Messages

References

Test Your Knowledge



Breast Imaging may be required as part of workup for Incidental Breast findings on other imaging



Indeterminate hyperattenuating lesion in the upper outer right breast on CT for investigation of weight loss in a 59 y old (a). Mammographic assessment demonstrates corresponding segmental heterogenous microcalcifications (b,c).

Chapter Outline

Breast Anatomy

Anatomical Variants

Pregnancy and Lactation

Diagnostic Imaging Techniques

Disease of the Breast: Benign

Disease of the Breast: Malignant

Axilla

Interventional Procedures

Screening

High Risk Women

▶ **Communication**
▶ Breast Imaging Scenarios

Multidisciplinary Team Meeting

Take-Home Messages

References

Test Your Knowledge



Basic Considerations in Communicating with Patients



- Diagnostic breast imaging studies frequently reveal the need to obtain a definitive histological diagnosis.
- The radiologist interprets the images, determines the need and performs the biopsy.
- The radiologist receives the pathological results, determines concordance of the tissue diagnosis with the imaging concern and guides the patient toward the most appropriate treatment.
- The radiologist is also uniquely positioned to enhance the patient's understanding and acceptance of the pathological findings with gentle and artful optimism.
- To communicate with patients in order explain the benefits, risk and basic technical aspects of diagnostic imaging of the breast
- To communicate the benefits and risks of mammography screening
- To be able to communicate the results of a breast imaging examination, whenever necessary under supervision, to patients and their families based on the radiologic report by the end of the medical studies
- To be able to correctly suggest the most appropriate imaging examination depending on the clinical situation

Chapter Outline

Breast Anatomy

Anatomical Variants

Pregnancy and Lactation

Diagnostic Imaging Techniques

Disease of the Breast: Benign

Disease of the Breast: Malignant

Axilla

Interventional Procedures

Screening

High Risk Women

▶ **Communication**

▶ Basic Considerations in
Communicating with Patients

Multidisciplinary Team Meeting


Take-Home Messages

References

Test Your Knowledge



Considerations in Communicating with Health Professionals



Standardisation of breast imaging report classification facilitates clear communication between referrer and the radiologist regarding the likelihood of malignant findings and the need for further investigation.

Comparison of Imaging Classification Systems



Category	BI-RADS	European/Royal College of Radiologists Breast Group
0	Incomplete assessment <i>Need to review priors and/or complete additional imaging</i>	
1	Negative	Normal/no significant abnormality
2	Benign finding	Benign finding
3	Probably benign findings (< 2% risk of malignancy). <i>Short-term follow-up review at 6 months, then every 6-12 months for 1-2 years)</i>	Indeterminate/probably benign findings. <i>There is a small risk of malignancy. Further investigation is indicated.</i>
4	Suspicious abnormality – biopsy recommended	Findings suspicious of malignancy There is a moderate risk of malignancy
5	Malignant findings	Findings highly suspicious of malignancy
6	Known biopsy-proven malignancy, treatment pending.	

Chapter Outline

Breast Anatomy

Anatomical Variants

Pregnancy and Lactation

Diagnostic Imaging Techniques

Disease of the Breast: Benign

Disease of the Breast: Malignant

Axilla

Interventional Procedures

Screening

High Risk Women

Communication

► Multidisciplinary Team Meeting

Take-Home Messages

References

Test Your Knowledge




Considerations in Communicating with Health Professionals



NCI Dictionary of Cancer Terms: "Treatment planning approach in which a number of doctors who are experts in different specialties (disciplines) review and discuss the medical condition and treatment options of a patient"

Values that underlie an effective multidisciplinary team include:

- effective communication and coordination
- respect and trust
- solid implementation strategies
- transparency



Chapter Outline

Breast Anatomy

Anatomical Variants

Pregnancy and Lactation

Diagnostic Imaging Techniques

Disease of the Breast: Benign

Disease of the Breast: Malignant

Axilla

Interventional Procedures

Screening

High Risk Women

Communication

▶ **Multidisciplinary Team Meeting**

Take-Home Messages

References

Test Your Knowledge



Multidisciplinary Team Meeting



All breast cancer specialists will attend the Multidisciplinary Team Meeting (MTM) on a regular basis in order to provide excellent breast cancer care: (oncoplastic) surgeon, medical oncologist, radiation oncologist, pathologist, radiologist and nuclear medicine physician.

The role for the radiologist at MTM is to demonstrate and explain imaging findings per patient, in order to facilitate a proper treatment plan in consensus with the other specialists.

If the management is agreed at MTM, treatment plan can be discussed with the patient.

In the case of discordant findings, repeat imaging with or without biopsy can be considered.



Chapter Outline

Breast Anatomy

Anatomical Variants

Pregnancy and Lactation

Diagnostic Imaging Techniques

Disease of the Breast: Benign

Disease of the Breast: Malignant

Axilla

Interventional Procedures

Screening

High Risk Women

Communication

▶ **Multidisciplinary Team Meeting**

Take-Home Messages

References

Test Your Knowledge



Take-Home Messages



- Imaging is used as part of **triple assessment** to diagnose and exclude disease.
- **Mammography** is the cornerstone of breast imaging, playing a crucial role as the screening imaging technique in women with average-risk of developing breast cancer.
- **DBT** is a mammography-based imaging technique that produces quasi-3D images of the breast, reducing the limitations of 2D imaging (overlapping tissues) and improving the detection and the delineation of findings, increasing the sensitivity and the specificity.
- **CEM** is a relatively new mammography-based imaging technique that relies on the intravenous administration of an iodinated contrast agent to highlight areas of increased contrast agent uptake; currently it can be considered as an alternative for women with contraindications to breast MRI.
- **Breast US** is a dynamic non-ionizing, accessible and cheap imaging technique that plays a very important role in the everyday practice by providing additional screening in women with dense breasts, by allowing direct real-time correlation of imaging and clinical findings and by guiding biopsies and other interventional procedure.

Chapter Outline

Breast Anatomy

Anatomical Variants

Pregnancy and Lactation

Diagnostic Imaging Techniques

Disease of the Breast: Benign

Disease of the Breast: Malignant

Axilla

Interventional Procedures

Screening

High Risk Women

Communication

Multidisciplinary Team Meeting

▶ Take-Home Messages

References

Test Your Knowledge



Take-Home Messages



- **Breast MRI** is a multiparametric imaging technique that has changed Breast Imaging, playing a very important role in different scenarios, such as in breast cancer staging, in the evaluation of response to neoadjuvant therapy and in the screening of women with high-risk of developing breast cancer and in women with extremely dense breasts.
- **Image guided biopsy** for diagnosis are used extensively; minimally invasive treatment becoming more popular in good prognosis disease such as DCIS and low grade cancer.
- Knowledge of the anatomy, anatomical variants and changes during pregnancy and lactation is important to recognize disease
- Imaging findings should be evaluated together with signs and symptoms. They should be compared with previous examinations.
- **Mammography** is the first-line imaging tool for patients over 40 years of age. Targeted ultrasound can be done in the presence of suspicious findings or if the patient has an extremely dense breast.

Chapter Outline

Breast Anatomy

Anatomical Variants

Pregnancy and Lactation

Diagnostic Imaging Techniques

Disease of the Breast: Benign

Disease of the Breast: Malignant

Axilla

Interventional Procedures

Screening

High Risk Women

Communication

Multidisciplinary Team Meeting

▶ Take-Home Messages

References

Test Your Knowledge



Take-Home Messages



- **Ultrasound** is the first-line imaging tool for patients under 40 years of age.
- **Benign diseases** of the breast, especially cysts and fibroadenomas are the most common and symptomatic masses in women.
- **Contrast-enhanced MRI** is a problem-solving tool with the highest sensitivity and negative predictive value for breast cancer detection.
- Some high-grade aggressive tumours (medullary type, grade 3 or triple-negative type etc.) can mimic benign masses on mammography/ultrasound. In patients with a family history, attention should be paid to newly developing lesions or masses showing increased size during follow-up. These masses should be confirmed by biopsy.
- Imaging the axilla to determine if there any abnormal lymph nodes is part of preoperative staging
- Clear communication of results with a management plan is part of the role of the radiologist.

Chapter Outline

Breast Anatomy

Anatomical Variants

Pregnancy and Lactation

Diagnostic Imaging Techniques

Disease of the Breast: Benign

Disease of the Breast: Malignant

Axilla

Interventional Procedures

Screening

High Risk Women

Communication

Multidisciplinary Team Meeting

▶ **Take-Home Messages**

References

Test Your Knowledge



References



Breast Anatomy

<https://www.acr.org/Clinical-Resources/Reporting-and-Data-Systems/Bi-Rads>

Anatomical Variants

Wendie A. Berg & Jessica: Leung Diagnostic Imaging: Breast, 3rd Edition Authors Date of Publication: 09/2019

García CJ, Espinoza A, Dinamarca V, Navarro O, Daneman A, García H, Cattani A. Breast US in children and adolescents. Radiographics. 2000 Nov-Dec;20(6):1605-12. doi: 10.1148/radiographics.20.6.g00nv171605. PMID: 11112814.

Chung EM, Cube R, Hall GJ, González C, Stocker JT, Glassman LM. From the archives of the AFIP: breast masses in children and adolescents: radiologic-pathologic correlation. Radiographics. 2009 May-Jun;29(3):907-31. doi: 10.1148/rg.293095010. PMID: 19448124.

Pregnancy and Lactation

Kaneda HJ, Mack J, Kasales CJ, Schetter S. Pediatric and adolescent breast masses: a review of pathophysiology, imaging, diagnosis, and treatment. AJR Am J Roentgenol. 2013 Feb;200(2):W204-12. doi: 10.2214/AJR.12.9560. PMID: 23345385.

de Holanda AA, Gonçalves AK, de Medeiros RD, de Oliveira AM, Maranhão TM. Ultrasound findings of the physiological changes and most common breast diseases during pregnancy and lactation. Radiol Bras. 2016 Nov-Dec;49(6):389-396. doi: 10.1590/0100-3984.2015.0076. PMID: 28057965; PMCID: PMC5210035.

Nissan N, Bauer E, Moss Massasa EE, Sklair-Levy M. Breast MRI during pregnancy and lactation: clinical challenges and technical advances. Insights Imaging. 2022 Apr 9;13(1):71. doi: 10.1186/s13244-022-01214-7. PMID: 35397082; PMCID: PMC8994812.

Chapter Outline

Breast Anatomy

Anatomical Variants

Pregnancy and Lactation

Diagnostic Imaging Techniques

Disease of the Breast: Benign

Disease of the Breast: Malignant

Axilla

Interventional Procedures

Screening

High Risk Women

Communication

Multidisciplinary Team Meeting

Take-Home Messages

▶ **References**

Test Your Knowledge



References



Diagnostic Imaging Techniques

Joe, B.N. and Lee, A.Y. (2022) *Breast Imaging: The Core Requisites*. 4th edn. Philadelphia, PA: Elsevier (The Core Requisites).

Berg, W.A. and Leung, J.W.T. (2019) *Diagnostic Imaging: Breast*. 3rd edn. Philadelphia, PA: Elsevier.

Fuchsjäger M., Morris E., Helbich T.H., *Breast Imaging: Diagnosis and Intervention*. 1st edn. Springer.

European Commission. European Guidelines for Quality Assurance in Breast Cancer Screening and Diagnosis. 4th edition. In Perry N, Broeders M, de Wolf C et al. (eds): Office for Official Publications of the European Communities, Luxembourg: 2006.

Kopans D. B. (2014). Digital breast tomosynthesis from concept to clinical care. *AJR. American journal of roentgenology*, 202(2), 299–308. <https://doi.org/10.2214/AJR.13.11520>.

Sensakovic WF, Carnahan MB, Czaplicki CD, Fahrenholtz S, Panda A, Zhou Y, Pavlicek W, Patel B. Contrast-enhanced Mammography: How Does It Work? *Radiographics*. 2021 May-Jun;41(3):829-839. doi: 10.1148/rg.2021200167. Epub 2021 Apr 9. PMID: 33835871.

Galati F, Moffa G, Pediconi F. Breast imaging: Beyond the detection. *Eur J Radiol*. 2022 Jan;146:110051. doi: 10.1016/j.ejrad.2021.110051. Epub 2021 Nov 19. PMID: 34864426.

Chapter Outline

Breast Anatomy

Anatomical Variants

Pregnancy and Lactation

Diagnostic Imaging Techniques

Disease of the Breast: Benign

Disease of the Breast: Malignant

Axilla

Interventional Procedures

Screening

High Risk Women

Communication

Multidisciplinary Team Meeting

Take-Home Messages

▶ References

Test Your Knowledge



References



Disease of the Breast: Benign

Berg WA et al. Cystic lesions of the breast: sonographic-pathologic correlation. *Radiology*. 2003;227(1):183-91

Wendie A. Berg, Jessica Leung. *Diagnostic Imaging Breast* (2019, Elsevier).

Oligane HC et al. Grouped amorphous calcifications at mammography: frequently atypical but rarely associated with aggressive malignancy. *Radiology*. 2018; 288(3):671-679

Chao TC, Chao HH, Chen MF. Sonographic features of breast hamartomas. *J Ultrasound Med*. 2007;26 (4): 447-52.

Malherbe K, Khan M, Fatima S. Fibrocystic Breast Disease. [Updated 2022 Aug 8]. In: StatPearls [Internet].

Bonnie N.Joe, Amie Y. Lee. *The core requisites* (4th edition,Elsevier)

Cheng L et al. Mastitis, a radiographic, clinical, and histopathologic review. *Breast J*. 2015; 21(4):403-9

Trop I et al. Breast abscesses: evidence-based algorithms for diagnosis, management, and follow-up. *Radiographics*. 2011; 31(6):1683-99

Mahoney MC et al. Breast emergencies: types, imaging features, and management. *AJR Am J Roentgenol*. 2014; 202(4):W390-9.

Hassan HHM et al. Fat necrosis of the breast: magnetic resonance imaging characteristics and pathologic correlation. *Acad Radiol*. 2018; 25(8):985-92

Taboada J, Stephens T, Krishnamurthy S, Brandt K, Whitman G. The Many Faces of Fat Necrosis in the Breast. *AJR Am J Roentgenol*. 2009;192(3):815-25

Ritse M. Mann, Nariya Cho, and Linda Moy. Breast MRI: State of the Art. *Radiology*. 2019; 292:3, 520-536

Chapter Outline

Breast Anatomy

Anatomical Variants

Pregnancy and Lactation

Diagnostic Imaging Techniques

Disease of the Breast: Benign

Disease of the Breast: Malignant

Axilla

Interventional Procedures

Screening

High Risk Women

Communication

Multidisciplinary Team Meeting

Take-Home Messages

▶ References

Test Your Knowledge



References



Interventional Procedures

Bick U, Trimboli RM, Athanasiou A et al. Image-guided breast biopsy and localisation: recommendations for information to women and referring physicians by the European Society of Breast Imaging. *Insights Imaging*. 2020 Feb 5;11(1):12. doi: 10.1186/s13244-019-0803-x.

O'Flynn EA, Wilson AR, Michell MJ. Image-guided breast biopsy: state-of-the-art. *Clin Radiol*. 2010 Apr;65(4):259-70. doi: 10.1016/j.crad.2010.01.008.

Giannotti E, James JJ, Chen Y, Sun R, Karuppiyah A, Yemm J, Lee AHS. Effectiveness of percutaneous vacuum-assisted excision (VAE) of breast lesions of uncertain malignant potential (B3 lesions) as an alternative to open surgical biopsy. *Eur Radiol*. 2021 Dec;31(12):9540-9547. doi: 10.1007/s00330-021-08060-z. Epub 2021 Jun 8. Erratum in: *Eur Radiol*. 2021 Jul 5; PMID: 34100998

Mauri G, Sconfienza LM, Pescatori LC, Fedeli MP, Alì M, Di Leo G, Sardanelli F. Technical success, technique efficacy and complications of minimally-invasive imaging-guided percutaneous ablation procedures of breast cancer: A systematic review and meta-analysis. *Eur Radiol*. 2017 Aug;27(8):3199-3210. doi: 10.1007/s00330-016-4668-9.

Sharma N, Cornford E, Cheung S, Price H, Kearins O. The impact of vacuum-assisted excision in the management of indeterminate B3 lesions in the NHS Breast Screening Programme in England. *Clin Radiol*. 2021 Jun;76(6):470.e23-470.e29. doi: 10.1016/j.crad.2021.01.021.

Screening

IDoR Publication 2016 *SCREENING & BEYOND Medical imaging in the Detection, Diagnosis and Management of Breast Diseases* https://www.internationaldayofradiology.com/app/uploads/2017/09/IDoR-2016_Book-on-Breast-Imaging_Web_low.pdf

Sardanelli F, Fallenberg EM, Clauser P, Trimboli R, Camps-Herrero J, Helbich TH, Forrai G. *Mammography: an update of the EUSOBI recommendations on information for women*. <https://www.eusobi.org/breast-imaging-publications-and-guidelines/>

Yaffe MJ, Jong RA, Pritchard, KI. Breast Cancer Screening: Beyond Mortality. *Journal of Breast Imaging*, Volume 1, Issue 3 September 2019, Pages 161-165

<https://healthcare-quality.jrc.ec.europa.eu/ecibc/european-breast-cancer-guidelines/screening-ages-and-frequencies>

Chapter Outline

Breast Anatomy

Anatomical Variants

Pregnancy and Lactation

Diagnostic Imaging Techniques

Disease of the Breast: Benign

Disease of the Breast: Malignant

Axilla

Interventional Procedures

Screening

High Risk Women

Communication

Multidisciplinary Team Meeting

Take-Home Messages

▶ References

Test Your Knowledge



References



High Risk Women

Monticciolo DL, Newell MS, Moy L, Niell B, Monsees B, Sickles EA. Breast Cancer Screening in Women at Higher-Than-Average Risk: Recommendations From the ACR. *J Am Coll Radiol*. 2018 Mar;15(3 Pt A):408-414. doi: 10.1016/j.jacr.2017.11.034.

Sardanelli F et al. Position paper on screening for breast cancer by the European Society of Breast Imaging (EUSOBI) and 30 national breast radiology bodies from Austria, Belgium, Bosnia and Herzegovina, Bulgaria, Croatia, Czech Republic, Denmark, Estonia, Finland, France, Germany, Greece, Hungary, Iceland, Ireland, Italy, Israel, Lithuania, Moldova, The Netherlands, Norway, Poland, Portugal, Romania, Serbia, Slovakia, Spain, Sweden, Switzerland and Turkey. *Eur Radiol*. 2017 Jul;27(7):2737-2743. doi: 10.1007/s00330-016-4612-z.

Thomas PS. Diagnosis and Management of High-Risk Breast Lesions. *J Natl Compr Canc Netw*. 2018 Nov;16(11):1391-1396. doi: 10.6004/jnccn.2018.7099.

Mann RM et al. European Society of Breast Imaging (EUSOBI). Breast cancer screening in women with extremely dense breasts recommendations of the European Society of Breast Imaging (EUSOBI). *Eur Radiol*. 2022 Jun;32(6):4036-4045. doi: 10.1007/s00330-022-08617-6.

Communication

IDoR Publication 2016 *SCREENING & BEYOND Medical imaging in the Detection, Diagnosis and Management of Breast Diseases*
https://www.internationaldayofradiology.com/app/uploads/2017/09/IDoR-2016_Book-on-Breast-Imaging_Web_low.pdf

Sardanelli F, Fallenberg EM, Clauser P, Trimboli R, Camps-Herrero J, Helbich TH, Forrai G. *Mammography: an update of the EUSOBI recommendations on information for women*. <https://www.eusobi.org/breast-imaging-publications-and-guidelines/>

Evans A, Trimboli RM, Athanasiou A, Balleyguier C, Baltzer P et al *Breast ultrasound: recommendations for information to women and referring physicians by the European Society of Breast Imaging*. <https://www.eusobi.org/breast-imaging-publications-and-guidelines/>

Maxwell AJ, Ridley NT, Rubin G, Wallis MG, Gilbert FJ and Michell M *The Royal College of Radiologists Breast Group breast imaging classification*. *Clinical Radiology*, 64, 2009, Pages 624-627

Chapter Outline

Breast Anatomy

Anatomical Variants

Pregnancy and Lactation

Diagnostic Imaging Techniques

Disease of the Breast: Benign

Disease of the Breast: Malignant

Axilla

Interventional Procedures

Screening

High Risk Women

Communication

Multidisciplinary Team Meeting

Take-Home Messages

▶ **References**

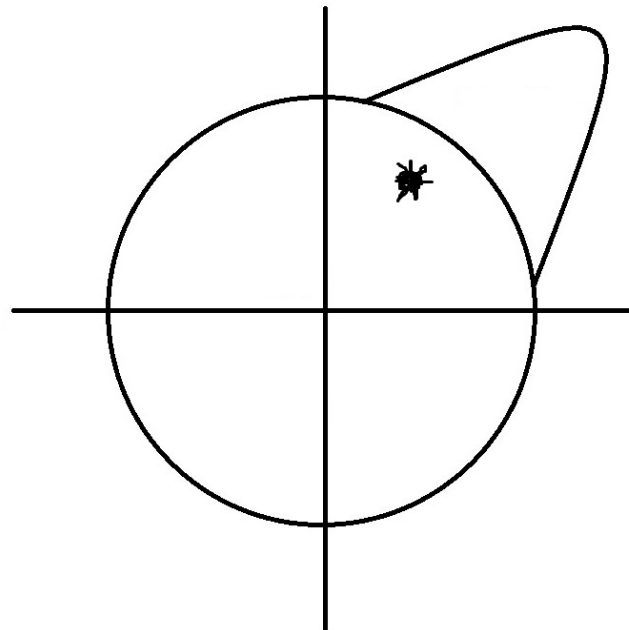
Test Your Knowledge



Test Your Knowledge

1. How would you describe the location of the lesion?

- Upper outer quadrant
- Upper inner quadrant
- Lower outer quadrant
- Lower inner quadrant



Chapter Outline

Breast Anatomy

Anatomical Variants

Pregnancy and Lactation

Diagnostic Imaging Techniques

Disease of the Breast: Benign

Disease of the Breast: Malignant

Axilla

Interventional Procedures

Screening

High Risk Women

Communication

Multidisciplinary Team Meeting

Take-Home Messages

References

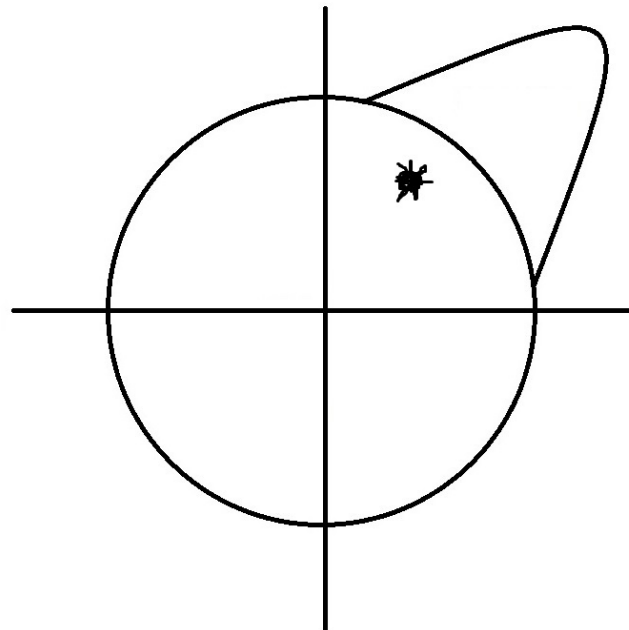
▶ Test Your Knowledge



Test Your Knowledge

1. How would you describe the location of the lesion?

- ✓ Upper outer quadrant
- Upper inner quadrant
- Lower outer quadrant
- Lower inner quadrant



Chapter Outline

Breast Anatomy

Anatomical Variants

Pregnancy and Lactation

Diagnostic Imaging Techniques

Disease of the Breast: Benign

Disease of the Breast: Malignant

Axilla

Interventional Procedures

Screening

High Risk Women

Communication

Multidisciplinary Team Meeting

Take-Home Messages

References

▶ Test Your Knowledge



Test Your Knowledge



2. What is the name of the syndrome consisting of unilateral partial or complete absence of the m. pectoralis, with associated breast hypo/aplasia and possible rib/chest wall deformities?

- Holland syndrome
- Poland syndrome
- Germany syndrome
- Switzerland syndrome



Chapter Outline

Breast Anatomy

Anatomical Variants

Pregnancy and Lactation

Diagnostic Imaging Techniques

Disease of the Breast: Benign

Disease of the Breast: Malignant

Axilla

Interventional Procedures

Screening

High Risk Women

Communication

Multidisciplinary Team Meeting

Take-Home Messages

References

▶ Test Your Knowledge



Test Your Knowledge



2. What is the name of the syndrome consisting of unilateral partial or complete absence of the m. pectoralis, with associated breast hypo/aplasia and possible rib/chest wall deformities?

- Holland syndrome
- ✓ Poland syndrome
- Germany syndrome
- Switzerland syndrome



Chapter Outline

Breast Anatomy

Anatomical Variants

Pregnancy and Lactation

Diagnostic Imaging Techniques

Disease of the Breast: Benign

Disease of the Breast: Malignant

Axilla

Interventional Procedures

Screening

High Risk Women

Communication

Multidisciplinary Team Meeting

Take-Home Messages

References

▶ Test Your Knowledge



Test Your Knowledge



3. Pregnancy and Lactation: What are the most seen ultrasound findings in a lactating breast?
 - Decreased parenchymal echogeniety and cysts
 - Decreased parenchymal echogeniety and dilated ducts
 - Increased parenchymal echogeniety and cysts
 - Increased parenchymal echogeniety and dilated ducts



Chapter Outline

Breast Anatomy

Anatomical Variants

Pregnancy and Lactation

Diagnostic Imaging Techniques

Disease of the Breast: Benign

Disease of the Breast: Malignant

Axilla

Interventional Procedures

Screening

High Risk Women

Communication

Multidisciplinary Team Meeting

Take-Home Messages

References

▶ Test Your Knowledge



Test Your Knowledge



3. Pregnancy and Lactation: What are the most seen ultrasound findings in a lactating breast?
- Decreased parenchymal echogeniety and cysts
 - Decreased parenchymal echogeniety and dilated ducts
 - Increased parenchymal echogeniety and cysts
 - ✓ Increased parenchymal echogeniety and dilated ducts



Chapter Outline

Breast Anatomy

Anatomical Variants

Pregnancy and Lactation

Diagnostic Imaging Techniques

Disease of the Breast: Benign

Disease of the Breast: Malignant

Axilla

Interventional Procedures

Screening

High Risk Women

Communication

Multidisciplinary Team Meeting

Take-Home Messages

References

▶ Test Your Knowledge



Test Your Knowledge



4. Regarding Breast Ultrasound (US), select the **TRUE** statement:
- Breast US is an imaging technique that exploits the magnetism of the protons that constitute the breast (and surrounding) tissues to create diagnostic images.
 - The American College of Radiology (ACR) recommends performing Breast US using low-frequency transducers, with a broad bandwidth operating at a center frequency of no more than 5 MHz.
 - Elastography is a modality of Breast US that allows the evaluation of stiffness.
 - One of the main advantages of Breast US is that it is an “operator-independent” imaging technique.
 - Breast US is contraindicated in the evaluation of symptomatic young or lactating patients.



Chapter Outline

Breast Anatomy

Anatomical Variants

Pregnancy and Lactation

Diagnostic Imaging Techniques

Disease of the Breast: Benign

Disease of the Breast: Malignant

Axilla

Interventional Procedures

Screening

High Risk Women

Communication

Multidisciplinary Team Meeting

Take-Home Messages

References

▶ Test Your Knowledge



Test Your Knowledge



4. Regarding Breast Ultrasound (US), select the **TRUE** statement:
- Breast US is an imaging technique that exploits the magnetism of the protons that constitute the breast (and surrounding) tissues to create diagnostic images.
 - The American College of Radiology (ACR) recommends performing Breast US using low-frequency transducers, with a broad bandwidth operating at a center frequency of no more than 5 MHz.
 - ✓ Elastography is a modality of Breast US that allows the evaluation of stiffness.
 - One of the main advantages of Breast US is that it is an “operator-independent” imaging technique.
 - Breast US is contraindicated in the evaluation of symptomatic young or lactating patients.



Chapter Outline

Breast Anatomy

Anatomical Variants

Pregnancy and Lactation

Diagnostic Imaging Techniques

Disease of the Breast: Benign

Disease of the Breast: Malignant

Axilla

Interventional Procedures

Screening

High Risk Women

Communication

Multidisciplinary Team Meeting

Take-Home Messages

References

▶ Test Your Knowledge



Test Your Knowledge



5. Which of the following characteristic does NOT indicate a malignancy on ultrasound?

- Irregular shape
- Shadowing
- Parallel orientation
- Not-circumscribed margins



Chapter Outline

Breast Anatomy

Anatomical Variants

Pregnancy and Lactation

Diagnostic Imaging Techniques

Disease of the Breast: Benign

Disease of the Breast: Malignant

Axilla

Interventional Procedures

Screening

High Risk Women

Communication

Multidisciplinary Team Meeting

Take-Home Messages

References

▶ Test Your Knowledge



Test Your Knowledge



5. Which of the following characteristic does NOT indicate a malignancy on ultrasound?

- Irregular shape
- Shadowing
- ✓ Parallel orientation
- Not-circumscribed margins



Chapter Outline

Breast Anatomy

Anatomical Variants

Pregnancy and Lactation

Diagnostic Imaging Techniques

Disease of the Breast: Benign

Disease of the Breast: Malignant

Axilla

Interventional Procedures

Screening

High Risk Women

Communication

Multidisciplinary Team Meeting

Take-Home Messages

References

▶ Test Your Knowledge



Test Your Knowledge



6. Which of these is a main advantage of breast Magnetic Resonance?

- High soft-tissue contrast
- Costs
- Scanning times
- Use in claustrophobic patients



Chapter Outline

Breast Anatomy

Anatomical Variants

Pregnancy and Lactation

Diagnostic Imaging Techniques

Disease of the Breast: Benign

Disease of the Breast: Malignant

Axilla

Interventional Procedures

Screening

High Risk Women

Communication

Multidisciplinary Team Meeting

Take-Home Messages

References

▶ Test Your Knowledge



Test Your Knowledge



6. Which of these is a main advantage of breast Magnetic Resonance?

- ✓ High soft-tissue contrast
- Costs
- Scanning times
- Use in claustrophobic patients



Chapter Outline

Breast Anatomy

Anatomical Variants

Pregnancy and Lactation

Diagnostic Imaging Techniques

Disease of the Breast: Benign

Disease of the Breast: Malignant

Axilla

Interventional Procedures

Screening

High Risk Women

Communication

Multidisciplinary Team Meeting

Take-Home Messages

References

▶ Test Your Knowledge



Test Your Knowledge



7. Regarding Breast Magnetic Resonance Imaging (MRI) and Contrast-enhanced Mammography (CEM), select the **FALSE** statement:

- Breast MRI is an imaging technique that uses sound waves to visualize breast tissue.
- Comparing to other imaging techniques, Breast MRI produces images with superior soft-tissue contrast.
- Breast MRI is useful in the evaluation of breast implants.
- CEM is an imaging technique based on dual-energy mammographic acquisition after intravenous administration of an iodinated contrast agent.
- The *Field of View (FoV)* of CEM is limited comparing to that of Breast MRI.



Chapter Outline

Breast Anatomy

Anatomical Variants

Pregnancy and Lactation

Diagnostic Imaging Techniques

Disease of the Breast: Benign

Disease of the Breast: Malignant

Axilla

Interventional Procedures

Screening

High Risk Women

Communication

Multidisciplinary Team Meeting

Take-Home Messages

References

▶ Test Your Knowledge



Test Your Knowledge



7. Regarding Breast Magnetic Resonance Imaging (MRI) and Contrast-enhanced Mammography (CEM), select the **FALSE** statement:

- ✓ Breast MRI is an imaging technique that uses sound waves to visualize breast tissue.
- Comparing to other imaging techniques, Breast MRI produces images with superior soft-tissue contrast.
- Breast MRI is useful in the evaluation of breast implants.
- CEM is an imaging technique based on dual-energy mammographic acquisition after intravenous administration of an iodinated contrast agent.
- The *Field of View (FoV)* of CEM is limited comparing to that of Breast MRI.



Chapter Outline

Breast Anatomy

Anatomical Variants

Pregnancy and Lactation

Diagnostic Imaging Techniques

Disease of the Breast: Benign

Disease of the Breast: Malignant

Axilla

Interventional Procedures

Screening

High Risk Women

Communication

Multidisciplinary Team Meeting

Take-Home Messages

References

▶ Test Your Knowledge



Test Your Knowledge



8. What should a breast imaging report contain?

- Clinical information and indication
- Breast density - Tissue composition- enhancement pattern
- Assessment category
- Recommendations
- All



Chapter Outline

Breast Anatomy

Anatomical Variants

Pregnancy and Lactation

Diagnostic Imaging Techniques

Disease of the Breast: Benign

Disease of the Breast: Malignant

Axilla

Interventional Procedures

Screening

High Risk Women

Communication

Multidisciplinary Team Meeting

Take-Home Messages

References

▶ Test Your Knowledge



Test Your Knowledge



8. What should a breast imaging report contain?

- Clinical information and indication
- Breast density - Tissue composition- enhancement pattern
- Assessment category
- Recommendations
- ✓ All



Chapter Outline

Breast Anatomy

Anatomical Variants

Pregnancy and Lactation

Diagnostic Imaging Techniques

Disease of the Breast: Benign

Disease of the Breast: Malignant

Axilla

Interventional Procedures

Screening

High Risk Women

Communication

Multidisciplinary Team Meeting

Take-Home Messages

References

▶ Test Your Knowledge



Test Your Knowledge



9. Which of the following is included in the Triple Assessment of a suspicious breast lesion?

- Surgery
- Radiotherapy
- Clinical examination
- Family history



Chapter Outline

Breast Anatomy

Anatomical Variants

Pregnancy and Lactation

Diagnostic Imaging Techniques

Disease of the Breast: Benign

Disease of the Breast: Malignant

Axilla

Interventional Procedures

Screening

High Risk Women

Communication

Multidisciplinary Team Meeting

Take-Home Messages

References

▶ Test Your Knowledge



Test Your Knowledge



9. Which of the following is included in the Triple Assessment of a suspicious breast lesion?

- Surgery
- Radiotherapy
- ✓ Clinical examination
- Family history



Chapter Outline

Breast Anatomy

Anatomical Variants

Pregnancy and Lactation

Diagnostic Imaging Techniques

Disease of the Breast: Benign

Disease of the Breast: Malignant

Axilla

Interventional Procedures

Screening

High Risk Women

Communication

Multidisciplinary Team Meeting

Take-Home Messages

References

▶ Test Your Knowledge



Test Your Knowledge



10. What is the best imaging modality to depict cysts?

- Mammography
- Ultrasound
- MR
- CT



Chapter Outline

Breast Anatomy

Anatomical Variants

Pregnancy and Lactation

Diagnostic Imaging Techniques

Disease of the Breast: Benign

Disease of the Breast: Malignant

Axilla

Interventional Procedures

Screening

High Risk Women

Communication

Multidisciplinary Team Meeting

Take-Home Messages

References

▶ Test Your Knowledge



Test Your Knowledge



10. What is the best imaging modality to depict cysts?

- Mammography
- ✓ Ultrasound
- MR
- CT



Chapter Outline

Breast Anatomy

Anatomical Variants

Pregnancy and Lactation

Diagnostic Imaging Techniques

Disease of the Breast: Benign

Disease of the Breast: Malignant

Axilla

Interventional Procedures

Screening

High Risk Women

Communication

Multidisciplinary Team Meeting

Take-Home Messages

References

▶ Test Your Knowledge



Test Your Knowledge



11. Fibroadenoma

- is a malignant breast disease.
- is the most common solid mass in woman of all ages.
- necessitates biopsy if its diameter increases by more than 20 percent within 6 months.
- presents as a firm mass adherent to the surrounding tissue.



Chapter Outline

Breast Anatomy

Anatomical Variants

Pregnancy and Lactation

Diagnostic Imaging Techniques

Disease of the Breast: Benign

Disease of the Breast: Malignant

Axilla

Interventional Procedures

Screening

High Risk Women

Communication

Multidisciplinary Team Meeting

Take-Home Messages

References

▶ Test Your Knowledge



Test Your Knowledge



11. Fibroadenoma

- is a malignant breast disease.
- ✓ is the most common solid mass in woman of all ages.
- ✓ necessitates biopsy if its diameter increases by more than 20 percent within 6 months.
- presents as a firm mass adherent to the surrounding tissue.



Chapter Outline

Breast Anatomy

Anatomical Variants

Pregnancy and Lactation

Diagnostic Imaging Techniques

Disease of the Breast: Benign

Disease of the Breast: Malignant

Axilla

Interventional Procedures

Screening

High Risk Women

Communication

Multidisciplinary Team Meeting

Take-Home Messages

References

▶ Test Your Knowledge



Test Your Knowledge



12. Regarding Hamartoma, select the **FALSE** statement:

- can present as vague breast mass.
- contains integral epithelial and stromal components.
- can enlarge.
- needs core biopsy.



Chapter Outline

Breast Anatomy

Anatomical Variants

Pregnancy and Lactation

Diagnostic Imaging Techniques

Disease of the Breast: Benign

Disease of the Breast: Malignant

Axilla

Interventional Procedures

Screening

High Risk Women

Communication

Multidisciplinary Team Meeting

Take-Home Messages

References

▶ Test Your Knowledge



Test Your Knowledge



12. Regarding Hamartoma, select the **FALSE** statement:

- can present as vague breast mass.
- contains integral epithelial and stromal components.
- can enlarge.
- ✓ needs core biopsy.



Chapter Outline

Breast Anatomy

Anatomical Variants

Pregnancy and Lactation

Diagnostic Imaging Techniques

Disease of the Breast: Benign

Disease of the Breast: Malignant

Axilla

Interventional Procedures

Screening

High Risk Women

Communication

Multidisciplinary Team Meeting

Take-Home Messages

References

▶ Test Your Knowledge



Test Your Knowledge



13. Select the predisposing conditions for fat necrosis.

- Blunt trauma
- Surgery
- Spontaneous in diabetic patients
- Lipoma



Chapter Outline

Breast Anatomy

Anatomical Variants

Pregnancy and Lactation

Diagnostic Imaging Techniques

Disease of the Breast: Benign

Disease of the Breast: Malignant

Axilla

Interventional Procedures

Screening

High Risk Women

Communication

Multidisciplinary Team Meeting

Take-Home Messages

References

▶ Test Your Knowledge



Test Your Knowledge



13. Select the predisposing conditions for fat necrosis.

- Blunt trauma
- ✓ Surgery
- Spontaneous in diabetic patients
- Lipoma



Chapter Outline

- Breast Anatomy
- Anatomical Variants
- Pregnancy and Lactation
- Diagnostic Imaging Techniques
- Disease of the Breast: Benign
- Disease of the Breast: Malignant
- Axilla
- Interventional Procedures
- Screening
- High Risk Women
- Communication
- Multidisciplinary Team Meeting
- Take-Home Messages
- References
- ▶ Test Your Knowledge



Test Your Knowledge



14. Which of the following minimal invasive treatments does NOT use electromagnetic waves to achieve local tumour ablation?

- Radiofrequency
- Microwaves
- Laser ablation
- Cryoablation



Chapter Outline

Breast Anatomy

Anatomical Variants

Pregnancy and Lactation

Diagnostic Imaging Techniques

Disease of the Breast: Benign

Disease of the Breast: Malignant

Axilla

Interventional Procedures

Screening

High Risk Women

Communication

Multidisciplinary Team Meeting

Take-Home Messages

References

▶ Test Your Knowledge



Test Your Knowledge



14. Which of the following minimal invasive treatments does NOT use electromagnetic waves to achieve local tumour ablation?

- Radiofrequency
- Microwaves
- Laser ablation
- ✓ Cryoablation



Chapter Outline

Breast Anatomy

Anatomical Variants

Pregnancy and Lactation

Diagnostic Imaging Techniques

Disease of the Breast: Benign

Disease of the Breast: Malignant

Axilla

Interventional Procedures

Screening

High Risk Women

Communication

Multidisciplinary Team Meeting

Take-Home Messages

References

▶ Test Your Knowledge



Test Your Knowledge



15. Which of these factors is associated with an increased risk of breast cancer?

- Early menarche
- Late first pregnancy (after age 28 years)
- Nulliparity
- Late menopause
- All



Chapter Outline

Breast Anatomy

Anatomical Variants

Pregnancy and Lactation

Diagnostic Imaging Techniques

Disease of the Breast: Benign

Disease of the Breast: Malignant

Axilla

Interventional Procedures

Screening

High Risk Women

Communication

Multidisciplinary Team Meeting

Take-Home Messages

References

▶ Test Your Knowledge



Test Your Knowledge



15. Which of these factors is associated with an increased risk of breast cancer?

- Early menarche
- Late first pregnancy (after age 28 years)
- Nulliparity
- Late menopause

✓ All



Chapter Outline

Breast Anatomy

Anatomical Variants

Pregnancy and Lactation

Diagnostic Imaging Techniques

Disease of the Breast: Benign

Disease of the Breast: Malignant

Axilla

Interventional Procedures

Screening

High Risk Women

Communication

Multidisciplinary Team Meeting

Take-Home Messages

References

▶ Test Your Knowledge



Editors

Federica Pediconi [1]

Fiona J. Gilbert [2]

Assistant Editor

Francesca Galati [1]

Affiliation

Chairperson of Educational Committee of EUSOBI

[1] Department of Radiological, Oncological and Pathological Sciences, Sapienza University of Rome, Italy

Past President of EUSOBI

[2] Head of Department, Radiology Department, University of Cambridge, Cambridge, UK

Chapter Outline

Breast Anatomy

Anatomical Variants

Pregnancy and Lactation

Diagnostic Imaging Techniques

Disease of the Breast: Benign

Disease of the Breast: Malignant

Axilla

Interventional Procedures

Screening

High Risk Women

Communication

Multidisciplinary Team Meeting

Take-Home Messages

References

Test Your Knowledge





Authors

Anatomical Variants

Elisabetta Giannotti [1]

Maria Adele Marino [2]

Affiliation

[1] Cambridge University Hospital Trust, Cambridge, UK

[2] Department of Biomedical Sciences and Morphologic and Functional Imaging, University of Messina, Messina, Italy

Pregnancy and Lactation

Elisabetta Giannotti [1]

Maria Adele Marino [2]

Affiliation

[1] Cambridge University Hospital Trust, Cambridge, UK

[2] Department of Biomedical Sciences and Morphologic and Functional Imaging, University of Messina, Messina, Italy

Chapter Outline

Breast Anatomy

Anatomical Variants

Pregnancy and Lactation

Diagnostic Imaging Techniques

Disease of the Breast: Benign

Disease of the Breast: Malignant

Axilla

Interventional Procedures

Screening

High Risk Women

Communication

Multidisciplinary Team Meeting

Take-Home Messages

References

Test Your Knowledge





Authors

Diagnostic Imaging Techniques

Filipe Barros Alves [1]

Melis Baykara Uluhan [2]

Francesca Ferrara [3]

Pascal A.T. Baltzer [4]

Paola Clauser [4]

Affiliations

[1] Centro Hospitalar Universitário de S. João, EPE and Faculdade de Medicina da Universidade: do Porto, Porto, Portugal;

[2] Istanbul Training and Research Hospital, Istanbul, Turkey;

[3] Dipartimento di Diagnostica per Immagini, Radioterapia Oncologica ed Ematologia, Fondazione Policlinico Universitario "A. Gemelli", IRCCS, Rome, Italy;

[4] Department of Biomedical Imaging and Image-guided Therapy; Medical University of Vienna, Vienna, Austria

Chapter Outline

Breast Anatomy

Anatomical Variants

Pregnancy and Lactation

Diagnostic Imaging Techniques

Disease of the Breast: Benign

Disease of the Breast: Malignant

Axilla

Interventional Procedures

Screening

High Risk Women

Communication

Multidisciplinary Team Meeting

Take-Home Messages

References

Test Your Knowledge





Authors

Disease of the Breast: Benign

Melis Baykara Ulsan [1]

Filipe Barros Alves [2]

Francesca Ferrara [3]

Pascal A.T. Baltzer [4]

Paola Clauser [4]

Affiliations

[1] Istanbul Training and Research Hospital, Istanbul, Turkey;

[2] Centro Hospitalar Universitário de S. João, EPE and Faculdade de Medicina da Universidade: do Porto, Porto, Portugal;

[3] Dipartimento di Diagnostica per Immagini, Radioterapia Oncologica ed Ematologia, Fondazione Policlinico Universitario "A. Gemelli", IRCCS, Rome, Italy;

[4] Department of Biomedical Imaging and Image-guided Therapy; Medical University of Vienna, Vienna, Austria

Chapter Outline

Breast Anatomy

Anatomical Variants

Pregnancy and Lactation

Diagnostic Imaging Techniques

Disease of the Breast: Benign

Disease of the Breast: Malignant

Axilla

Interventional Procedures

Screening

High Risk Women

Communication

Multidisciplinary Team Meeting

Take-Home Messages

References

Test Your Knowledge





Authors

Disease of the Breast: Malignant

Chantal Van Ongeval [1]

Affiliations

[1] UZ Leuven, University Hospitals of Leuven, Faculty of Medicine, University of Leuven, Belgium

Chapter Outline

Breast Anatomy

Anatomical Variants

Pregnancy and Lactation

Diagnostic Imaging Techniques

Disease of the Breast: Benign

Disease of the Breast: Malignant

Axilla

Interventional Procedures

Screening

High Risk Women

Communication

Multidisciplinary Team Meeting

Take-Home Messages

References

Test Your Knowledge

Chantal.vanongeval@uzleuven.be





Authors

Axilla

Fleur Kilburn-Toppin [1]

Thiemo J.A. van Nijnatten [2]

Affiliations

[1] Cambridge Breast Unit, Cambridge University Hospital NHS Foundation Trust, Addenbrookes' Hospital, Hills Road, Cambridge CB2 0QQ, UK

[2] Department of Radiology and Nuclear Medicine, Maastricht University Medical Center+, the Netherlands

Chapter Outline

Breast Anatomy

Anatomical Variants

Pregnancy and Lactation

Diagnostic Imaging Techniques

Disease of the Breast: Benign

Disease of the Breast: Malignant

Axilla

Interventional Procedures

Screening

High Risk Women

Communication

Multidisciplinary Team Meeting

Take-Home Messages

References

Test Your Knowledge





Authors

Interventional Procedures

Rubina Manuela Trimboli [1]

Giulia Vatteroni [2]

Affiliations

[1] IRCCS Humanitas Research Hospital, Via Manzoni 56, 20089 Rozzano, Milan, Italy

[2] Department of Biomedical Sciences, Humanitas University, Via Rita Levi Montalcini 4, Pieve Emanuele, Milan, Italy

Chapter Outline

Breast Anatomy

Anatomical Variants

Pregnancy and Lactation

Diagnostic Imaging Techniques

Disease of the Breast: Benign

Disease of the Breast: Malignant

Axilla

Interventional Procedures

Screening

High Risk Women

Communication

Multidisciplinary Team Meeting

Take-Home Messages

References

Test Your Knowledge

trimboli.rm@gmail.com
giulia.vatteroni@gmail.com





Authors

Screening

Jessica Muscat [1]

Affiliations

[1] Medical Imaging Department, Mater Dei Hospital, Msida, Malta

Chapter Outline

Breast Anatomy

Anatomical Variants

Pregnancy and Lactation

Diagnostic Imaging Techniques

Disease of the Breast: Benign

Disease of the Breast: Malignant

Axilla

Interventional Procedures

Screening

High Risk Women

Communication

Multidisciplinary Team Meeting

Take-Home Messages

References

Test Your Knowledge

jessica.muscat@gov.mt





Authors

High Risk Women

Elisabetta Giannotti [1]

Maria Adele Marino [2]

Affiliations

[1] Cambridge University Hospital Trust, Cambridge, UK

[2] Department of Biomedical Sciences and Morphologic and Functional Imaging, University of Messina, Messina, Italy

Chapter Outline

Breast Anatomy

Anatomical Variants

Pregnancy and Lactation

Diagnostic Imaging Techniques

Disease of the Breast: Benign

Disease of the Breast: Malignant

Axilla

Interventional Procedures

Screening

High Risk Women

Communication

Multidisciplinary Team Meeting

Take-Home Messages

References

Test Your Knowledge





Authors

Communication

Jessica Muscat [1]

Francesca Galati [2]

Affiliations

[1] Medical Imaging Department, Mater Dei Hospital, Msida, Malta

[2] Department of Radiological, Oncological and Pathological Sciences, Sapienza University of Rome, Italy

Chapter Outline

Breast Anatomy

Anatomical Variants

Pregnancy and Lactation

Diagnostic Imaging Techniques

Disease of the Breast: Benign

Disease of the Breast: Malignant

Axilla

Interventional Procedures

Screening

High Risk Women

Communication

Multidisciplinary Team Meeting

Take-Home Messages

References

Test Your Knowledge





Authors

Multidisciplinary Team Meeting

Fleur Kilburn-Toppin [1]

Thiemo J.A. van Nijnatten [2]

Francesca Galati [3]

Affiliations

[1] Cambridge Breast Unit, Cambridge University Hospital NHS Foundation Trust, Addenbrookes' Hospital, Hills Road, Cambridge CB2 0QQ, UK

[2] Department of Radiology and Nuclear Medicine, Maastricht University Medical Center+, the Netherlands

[3] Department of Radiological, Oncological and Pathological Sciences, Sapienza University of Rome, Italy

Chapter Outline

Breast Anatomy

Anatomical Variants

Pregnancy and Lactation

Diagnostic Imaging Techniques

Disease of the Breast: Benign

Disease of the Breast: Malignant

Axilla

Interventional Procedures

Screening

High Risk Women

Communication

Multidisciplinary Team Meeting

Take-Home Messages

References

Test Your Knowledge

fleurkilburntoppin@gmail.com
thiemo.nijnatten@mumc.nl
francesca.galati@uniroma1.it





Authors

Take-Home Messages

Federica Pediconi [1]

Fiona J. Gilbert [2]

Affiliations

[1] Department of Radiological, Oncological and Pathological Sciences, Sapienza University of Rome, Italy

[2] Head of Department, Radiology Department, University of Cambridge, Cambridge, UK

Chapter Outline

Breast Anatomy

Anatomical Variants

Pregnancy and Lactation

Diagnostic Imaging Techniques

Disease of the Breast: Benign

Disease of the Breast: Malignant

Axilla

Interventional Procedures

Screening

High Risk Women

Communication

Multidisciplinary Team Meeting

Take-Home Messages

References

Test Your Knowledge





Authors

Test Your Knowledge

Mirjam Wielema [1]

Federica Pediconi [2]

Francesca Galati [2]

Affiliations

[1] University Medical Center Groningen and Elisabeth TweeSteden Hospital, The Netherlands

[2] Department of Radiological, Oncological and Pathological Sciences, Sapienza University of Rome, Italy

mirjamwielema@hotmail.com
federica.pediconi@uniroma1.it
francesca.galati@uniroma1.it



Chapter Outline

Breast Anatomy

Anatomical Variants

Pregnancy and Lactation

Diagnostic Imaging Techniques

Disease of the Breast: Benign

Disease of the Breast: Malignant

Axilla

Interventional Procedures

Screening

High Risk Women

Communication

Multidisciplinary Team Meeting

Take-Home Messages

References

Test Your Knowledge



All material used (including intellectual property and illustration elements) either originates from the authors, the authors were entitled to use the material by applicable law or have obtained a transferable license from the copyright holder.

Chapter Outline

Breast Anatomy

Anatomical Variants

Pregnancy and Lactation

Diagnostic Imaging Techniques

Disease of the Breast: Benign

Disease of the Breast: Malignant

Axilla

Interventional Procedures

Screening

High Risk Women

Communication

Multidisciplinary Team Meeting

Take-Home Messages

References

Test Your Knowledge